Kuwait Scientific Research Journal of Medical Sciences (KSRJMS)

ISSN Print: 2790-6574 | ISSN Online : 2790-6566 Open Access

Natal Tooth In a 20-Day-Old Infant: A Case Report And Review Of Literature

Dr. Shivani Bedarkar[1], Dr. Prasad Musale[2], Dr. Pranav Dave[3], Dr. Supraja Ganeshan[4], Dr. Vaishnavi Bele[5], Dr. Saloni Rajguru[6]

[1,4,5,6] Post graduate student, Department of Paediatric and Preventive Dentistry, SMBT Institutes of Dental Sciences and Research, Nashik 422403

[2]Professor and Head of Department, Department of Paediatric and Preventive Dentistry, SMBT Institutes of Dental Sciences and Research, Nashik 422403

[3]Associate Professor and Reader of Department of Paediatric and Preventive Dentistry, SMBT Institutes of Dental Sciences and Research, Nashik 422403

*Corresponding Author

Dr. Shivani Bedarkar
Department of Paediatric and Preventive Dentistry, SMBT Institutes of Dental Sciences and Research, Nandi hills, Igatpuri , Nashik

Email: shivanimbedarkar@gmail.com

Article History
Received: 15.08.2025
Revise : 29.08.2025
Accepted: 05.09.2025
Published: 11.09.2025

DOI:10.61705/KSRJMS.2.2.2025.1.4

Keywords: Natal teeth, neonatal dentistry, mandibular incisors, infant oral health, case report.

Abstract: Background: Natal teeth are teeth present at birth and are relatively rare developmental anomalies. Their occurrence can cause feeding difficulties and pose risks such as aspiration or ulceration.
Case Presentation: We report a case of a 20-day-old infant who presented with a single natal tooth in the mandibular anterior region. The tooth was slightly mobile, and the mother reported nipple discomfort during breastfeeding. Clinical examination confirmed a solitary natal tooth in the lower mandibular anterior region. Due to its mobility and associated maternal discomfort, extraction was performed under local anesthesia.
Conclusion: Natal teeth require individualized management based on tooth mobility, feeding interference, and risk of aspiration. Prompt evaluation and multidisciplinary care are essential for optimal outcomes.

Introduction

Natal teeth are defined as teeth present at birth, while neonatal teeth erupt within the first 30 days of life[1]. The incidence of natal teeth has been reported to range from 1 in 2,000 to 1 in 3,500 live births[2]. Most natal teeth are found in the mandibular anterior region, particularly at the site of the lower central incisors[3]. Although the etiology remains unclear, possible contributing factors include superficial position of the developing tooth germ, heredity, endocrine disturbances, and local factors such as infection or trauma[4].

Clinically, natal teeth can present as part of normal dentition erupting prematurely or as supernumerary teeth[5]. They may cause complications including feeding difficulties, risk of aspiration, or trauma to the infant's tongue (Riga-Fede disease) and to the mother's breast during nursing[6]. Therefore, careful diagnosis and

ISSN Print: 2790-6574 | ISSN Online : 2790-6566 Open Access

management are essential to prevent further complications.

This report describes a case of a 20-day-old infant presenting with a single natal tooth in the mandibular anterior region, with an emphasis on clinical management and literature correlation.

Case Presentation

A 20-day-old male infant was brought to the pediatric dental department by his mother, who complained of discomfort during breastfeeding. The mother noticed a small tooth-like structure in the baby's lower front gum since birth. The child was full-term and healthy, with no relevant prenatal or postnatal complications. Family history was non-contributory.

Intraoral examination revealed a single whitish structure resembling a tooth in the mandibular anterior region, corresponding to the position of the left central incisor. The tooth exhibited slight mobility and was approximately 3 mm in height. Surrounding gingival tissues appeared normal without ulceration or inflammation. No other erupted teeth were observed.

The clinical diagnosis of a natal tooth was established. Considering its mobility and maternal breastfeeding discomfort, extraction was planned to prevent the risk of aspiration. After obtaining parental consent, topical anesthetic gel followed by local infiltration of 2% lignocaine (0.1 mL) was administered. The tooth was carefully extracted using sterile forceps. Minimal bleeding was noted, and hemostasis was achieved with gentle pressure using sterile gauze. The extracted tooth had a poorly developed root structure. Post-extraction instructions were given to the mother, and the infant was re-evaluated after one week, showing uneventful healing and improved breastfeeding comfort.

Discussion

Natal teeth, although uncommon, have been well-documented in pediatric dental literature. Studies suggest that 85% of natal and neonatal teeth are part of the normal primary dentition, while 15% are supernumerary[7]. The mandibular central incisor region is the most frequently affected site[8].

In the present case, the tooth was located in the lower anterior region and exhibited slight mobility. The major concern was maternal discomfort during feeding and potential aspiration due to looseness. These factors justified extraction under local anesthesia.

Histologically, natal teeth generally exhibit incomplete root formation and reduced enamel thickness[9]. This incomplete development contributes to their mobility. Various management approaches have been proposed depending on the tooth's stability and associated complications. Stable teeth that do not interfere with feeding may be retained under observation, while mobile teeth or those causing trauma are recommended for extraction[10].

When extraction is indicated, it should ideally be performed after the neonatal period (≥10 days old) to allow for sufficient vitamin K–dependent clotting factors to develop[11]. In this case, the infant was 20 days old, and the extraction was safely carried out. Proper follow-up is crucial to ensure healing and normal eruption of subsequent primary teeth. In most cases, extraction of natal teeth does not affect normal tooth development[12].

Conclusion

Natal teeth, although rare, may pose feeding challenges and other potential risks. Early recognition and appropriate management, including parental counseling, are essential. Extraction is indicated in cases of mobility, interference with feeding, or risk of aspiration. Multidisciplinary coordination among pediatricians, dentists, and lactation consultants ensures comprehensive care for both infant and mother.

References

1. Massler M, Savara BS. Natal and neonatal teeth: A review of 24 cases reported in the literature. J Pediatr. 1950;36(3):349–359.

ISSN Print: 2790-6574 | ISSN Online : 2790-6566 Open Access

2. Kates GA, Needleman HL, Holmes LB. Natal and neonatal teeth: A clinical study. J Am Dent Assoc. 1984;109(3):441–443.
3. Leung AK, Robson WL. Natal teeth: A review. J Natl Med Assoc. 2006;98(2):226–228.
4. Cunha RF, Boer FA, Torriani DD, Frossard WT. Natal and neonatal teeth: Review of the literature. Pediatr Dent. 2001;23(2):158–162.
5. Bodenhoff J, Gorlin RJ. Natal and neonatal teeth: Folklore and fact. Pediatrics. 1963;32:1087–1093.
6. Hebling J, Zuanon AC, Vianna DR. Dentoalveolar anomalies in children with natal and neonatal teeth. Quintessence Int. 1997;28(12):845–848.
7. Zhu J, King D. Natal and neonatal teeth. ASDC J Dent Child. 1995;62(2):123–128.
8. Khandelwal V, Nayak UA, Nayak PA, Bafna Y. Management of natal teeth: A case report and review. J Clin Exp Dent. 2013;5(1):e37–e40.
9. Mhaske S, Yuwanati MB, Mhaske A, Ragavendra R, Kamath K, Saawarn S. Natal and neonatal teeth: An overview of the literature. ISRN Pediatr. 2013;2013:956269.
10. Allwright WC. Natal and neonatal teeth: A clinical and histological study. Br Dent J. 1958;105(6):163–172.
11. Leung AK, Robson WL. Natal teeth: Review of 50 cases. J Natl Med Assoc. 2006;98(2):226–228.
12. Rao RS, Mathad SV. Natal teeth: Case report and review. J Oral Maxillofac Pathol. 2009;13(1):41–46.



Figure 1 : Natal teeth in lower anterior region



Figure 2: Post Extraction

ISSN Print: 2790-6574 | ISSN Online : 2790-6566 Open Access

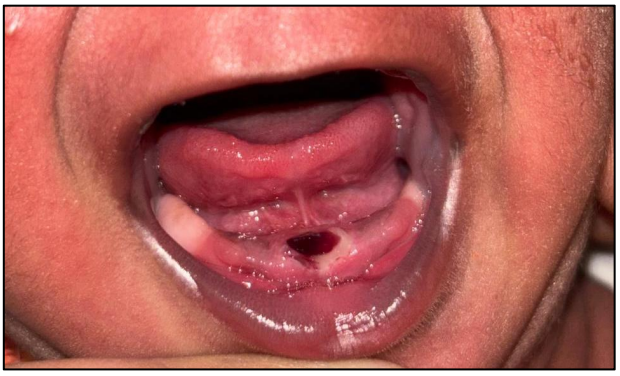

Figure: Blood Clot Formation after 1 hour of Extraction