Kuwait Research Journal of Agriculture and Life Science (KRJALS)

ISSN Print: 2790-6485 | ISSN Online : 2790-6477 Open Access

Long-Term Stanozolol Administration Induces Structural Testicular Damage and Spermatogenic Arrest: Histomorphometric Study in Male Rats

Marwa Ahmed Meri[1] , Baidaa Ghanem Algam[2], Alaa Shahid Jassim Al-Bdery[3]

[1]Lecturer, Ministry of Education, Directorate of Education of Al-Najaf Governorate, AL-Najaf, Iraq.

[2]Lecturer, Directorate General Education in Najaf Governorate, Iraq.

[3]Lectuer, Ph.D in Microbiology at Ministry of Education, Directorate of Education in Al-Najaf Al-Ashraf

*Corresponding Author

Marwa Ahmed Meri

Lecturer, Ministry of Education, Directorate of Education of Al-Najaf Governorate, AL-Najaf, Iraq.

Article History

Received: 07.01.2026

Revise : 20.02.2026

Accepted: 23.02.2026

Published: 25.02.2026

DOI:10.61705/KRJALS.5.1.2026.41.48

Keywords: Stanozolol, Spermatogenic Arrest, Testicular Morphometry, Anabolic Steroids, Reproductive Toxicity, Alopecia.

Abstract:

The long-term administration of anabolic-androgenic steroids (AAS), including Stanozolol, can disturb the endocrine balance and male reproductive function. The objective of this research was to investigate the prolonged histological-morphometric effects of Stanozolol on the tests and epididymis, as well as the weight changes and skin-hair conditions in an experimental model.

In a study, 80 adult male albino rats were randomly allocated to control and treated group. The treated group was intubated with Stanozolol 5 mg/kg/day by oral gavage for eight weeks. We kept an eye on their body weight every week. Following humane euthanasia, testicular and epididymal tissues were harvested and examined by using standard histological staining techniques of Hematoxylin and Eosin, Periodic Acid–Schiff, and Masson's Trichrome. Structural changes are evaluated by quantitative histomorphometry analysis.

Stanozolol caused a significant increase in body weight ($p \leq 0.05$) but also caused localized alopecia along with the thinning of hair coat. Microscopic analysis revealed seminiferous tubules atrophy, thickening of basement membrane, and total halting of spermatogenesis. Significant decrease in tubular diameter and germinal epithelial height was confirmed by morphometric measurements ($p \leq 0.05$). The epididymis exhibited a significant reduction in sperm count with excessive cellular debris in the lumen.

To sum up, Stanozolol might have caused anabolic growth to the body overall, but long-term use caused a huge amount of damage to the structural components of the male reproductive organs. Moreover, it also affected the condition of the skin and hair negatively. Findings indicate the risk of reproductive consequences of prolonged exposure to anabolic steroids.

Introduction

The primary role of the male reproductive system is fertility, which occurs through spermatogenesis (the formation of sperm cells) and steroidogenesis (the production of sex steroids). (Albano et al. 2021) The series of functions are managed by HPG Axis. The release of follicle-stimulating hormone and luteinizing hormone by gonadotropin-releasing hormone regulates the activity of Sertoli and Leydig cells in the testes (Al-Otaibi 2024). The reproduction function will decline, and structural abnormalities will develop if the hormonal balance is disturbed due to internal or external factors (Hashim and Thanoon, 2022).

Anabolic-androgenic steroids are synthetic variants of testosterone. Even though they are not therapeutically useful, they are often taken at high doses for the purpose of increasing muscle mass

ISSN Print: 2790-6485 | ISSN Online : 2790-6477 Open Access

and performance (Wenbo & Yan, 2023). Stanozolol is a very commonly abused compound. Prolonged exposure suppresses the HPG axis via negative feedback mechanisms, resulting in hypogonadism and impaired reproductive function (Bento-Silva et al., 2010; ElShebiney et al., 2025).

Stanozolol has effects beyond hormonal changes. Frequent use may impact skin and hair quality (Sessa et al., 2018) and increase body weight via nitrogen retention and muscle hypertrophy. Androgens such as testosterone and other androgenic agents have high biological activity. Androgens can damage the hair follicles. Alopecia is caused due to a reduction in the anagen phase of hair growth. This effect on hair growth is also reflected externally (Margo et al., 2022; Perry et al., 2017).

Prior research indicates that lengthy exposure to Stanozolol lowers gonadotropin secretion, reduces the levels of intratesticular testosterone, and hampers the structure of the testes (Salerno et al., 2018). The reported alterations consist of degeneration of spermatogonial tubule, disruption of germ cell layers, and distension of interstitial spaces caused by decreased Leydig cell function (Hijazi et al., 2012; Moss et al., 2022). Morphometric analyses also show a decrease in tubular diameter and germinal epithelial height that may eventually lead to spermatogenic arrest (Takahashi et al., 2004; Christou et al., 2017).

Chronic exposure to steroids may lead to tissue injury due to oxidative stress. Overproduction of reactive oxygen species can induce germ cell apoptosis and damage their DNA (Shokri et al., 2010; Pomara et al., 2015). There is a lack of a thorough histomorphometric comparison of treated and control groups under controlled circumstances despite existing studies (Nieschlag & Vorona, 2015; Karila et al., 2004).

In this regard, the present study was aimed to evaluate the chronic histological and morphometric effects of Stanozolol on testicular integrity and spermatogenesis in albino rats for 8 weeks. The present work attempts to elucidate the effects of anabolic steroid misuse upon male fertility more clearly by providing microscopic evidence.

Materials and Methods

2.1. Experimental Animals and Ethical Approval

The study comprised eighty healthy adult male albino rats (Rattus norvegicus) weighing about 225 ± 25 g and aged about 10–12 weeks. The animals were acquired from the Animal House in the College of Vet Medicine, University of Kufa. The ARRIVE guidelines and the international standards referenced guidance for all experimental procedures for laboratory animals (Kilkenny et al., 2010) The Institutional Ethics Committee of the University of Kufa approved this study ethically.

2.2. Housing and Environmental Conditions

Rats were kept inside polycarbonate cages, with five rats per cage, in a standard environment. The temperature, relative humidity and light–dark cycles were maintained at. 22 ± 2 ° C, 50-60% and 12 hours, respectively (Al-Otaibi, 2024). Animals were given free access to standard laboratory pellet diet and distilled water for testing. Prior to the beginning of the experiment, the rats were given a seven-day acclimation row to ensure their physiological stabilization (National Research Council 2011).

2.3. Experimental Design and Dosing

Once acclimatized, rats were divided randomly into two equal groups (n = 40) coloration investigation. The control group underwent no pharmacological treatment and was kept under the same standard conditions. The Stanozolol-treated class was administered Stanozolol at a dose of 5mg/kg/day. The drug was dissolved in corn oil and administrated by oral gavage for eight weeks consecutively to induce chronic exposure (Shokri et al., 2010; ElShebiney et al., 2025).

2.4. Anthropometric Assessment (Body Weight Measurement)

The body weight of each rat will be measured weekly by using a high-precision digital balance to assess the anabolic and systemic effects of Stanozolol. At the end of eight weeks, the formula of percentage of weight gain was calculated from the following:

ISSN Print: 2790-6485 | ISSN Online : 2790-6477 Open Access

Weight Gain (%) = [(Final Weight − Initial Weight) / Initial Weight] × 100

This measurement was used as an indicator of the metabolic influence of the steroid (Bento-Silva et al., 2010).

2.5. Euthanasia and Tissue Sampling

After eight weeks of experiment, overnight fasting was executed on the rat and anesthetization was performed through intraperitoneal injection of the ketamine (90 mg/kg) and xylazine (10 mg/kg) drug. Euthanasia was performed in accordance with approved protocols (AVMA Guidelines, 2020). The two testes were removed, cleaned of external adipose tissues, rinsed in ice-cold (0.9% NaCl) physiological saline, and finally weighed to determine gonadosomatic index (GSI).

2.6. Histological Processing

For a duration of 48 hours, Testicular tissues were fixed in 10% NBF. Next, the samples were dehydrated in graded ethanol, cleared in xylene, and embedded in paraffin wax through standard histological procedures. Using a rotary microtome, serial sections were cut into a thickness of 4–5 µm (Suvarna et al., 2018). Following staining methods were used.

- Hematoxylin and eosin (H&E): Giving general morphology of tissues and architecture
- Periodic Acid–Schiff (PAS) is used to identify the integrity of the basement membrane.
- Masson's Trichrome solution is used to measure interstitial fibrotic tissue thickness.

2.7 Histomorphometric Analysis

A digital imaging system (Olympus, Japan) was used for quantitative histomorphometric analysis. Ten circular seminiferous tubules were selected randomly from three different tissue sections of each rat. The next values were measured.

1. Seminiferous Tubule Diameter (µm) was measured on both its minor and major axis.
2. Germinal epithelial thickness µm was measured from basement membrane to tubular lumen.
3. Johnsen's score assesses spermatogenesis and evaluates the arrest of spermatogenic activity (1970; Takahashi et al. 2004).

2.8. Statistical Analysis

The handling of the statistical analysis was via SPSS. The values are shown as average ± standard deviation (SD). The independent samples t-test was used to assess differences between control and treated groups. A p value of ≤0.05 was statistically significant (Field, 2013).

3 . Results

3.1. General Observations and Anthropometric Data

3.1.1. Body Weight and Weight Gain

Statistical analysis indicated that the Stanozolol-treated group had a significantly higher final body weight and weight gain percentage ($p < 0.05$) than the control group. As the body mass increased, the anabolic effects in treated rats were evident. Even if the testicular weight whichever the time has reduced absolutely, it is nonetheless significantly increased at some stage and so systemic anabolic growth occurred of this type as well as structural impairment of reproductive organs (Table 3.1).

Table 3.1: Effects of eight-week Stanozolol administration on body weight and testicular weight in adult male rats.

Parameter	Control Group (n=40)	Stanozolol Group (n=40)	P-value
Initial Body Weight (g)	224.50 ± 12.30	226.10 ± 10.80	> 0.05 (NS)
Final Body Weight (g)	285.40 ± 15.60	342.75 ± 18.25*	< 0.05
Net Weight Gain (g)	60.90 ± 5.20	116.65 ± 9.40*	< 0.05
Weight Gain (%)	27.12%	51.59%	< 0.01
Absolute Testicular Weight (g)	3.15 ± 0.25	1.85 ± 0.15*	< 0.05
Gonadosomatic Index (GSI)	1.10 ± 0.08	0.53 ± 0.04*	< 0.01

**Statistically significant at p < 0.05.*
NS = Not significant.

Kuwait Research Journal of Agriculture and Life Science (KRJALS)

ISSN Print: 2790-6485 | ISSN Online : 2790-6477 Open Access

The findings were indicative of the anabolic effect of Stanozolol (Table 3.1). Rats which were treated showed a clear increase in body weight but both absolute testicular weight and gonadosomatic index (GSI) were significantly reduced. Despite gaining weight, there are signs of testicular atrophy.

3.1.2. Physical Appearance and Alopecia

The appearance of the integumentary system of Stanozolol-treated rats was clinically observed. After the fifth week, the animals showed thinning of the coat and loss of fur in localized patches, mostly over the dorsal. Conversely, the control rats had a glossy, dense, and intact fur throughout the experiment.

3.2. Histopathological Evaluation of Testicular Tissue

3.2.1. Control Group (Group I)

Examination of testicular sections from the control group when stained with H&E under the microscope showed normal and well-ordered tissue architecture. The seminiferous tubules were round to oval in shape and tightly packed with little interstitial space. The arrangement of germinal epithelium in layers and stages of spermatogenesis such as spermatogonia, primary and secondary spermatocytes and groups of mature spermatids was clear (Figure 3.1A). Sertoli cells were observed within the epithelium, offering structural support. Normal Leydig cell populations with prominent nuclei were present in the interstitial areas, which showed no edema or fibrosis.

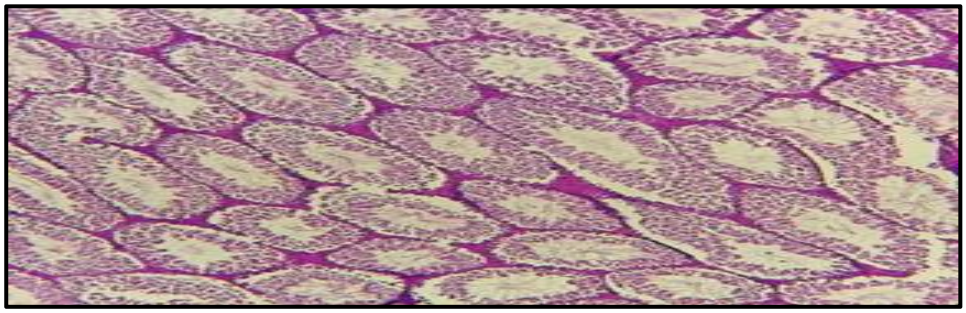

Figure 3.1A: Testicular section from the control group showing normal histological architecture (H&E stain, ×10).

3.2.2. Stanozolol-Treated Group (Group II)

Repeated stanozolol treatment caused severe changes in testis tissue. The atrophy was quite clear with apparent irregular, wavy basement membranes and reduction in size. The germinal layer appeared disorganized and considerably thinner, with some areas indicating spermatogenic arrest, representing stoppage development of germ cells from spermatocytes to mature spermatids (Figure 3.1B). We can see that there are degenerative features. There are cytoplasmic vacuolation within the germinal layers. There is desquamation of the germ cells into the tubular lumen. The interstitial spaces were widened, the Leydig cell populations were reduced and vascular congestion was occasionally observed.

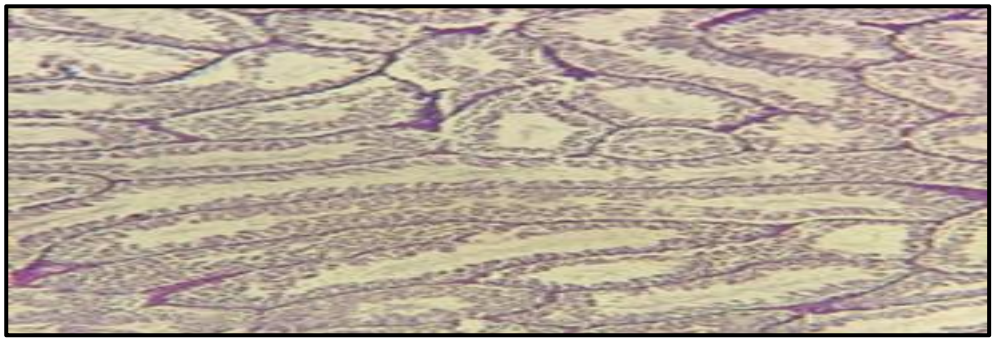

Figure 3.1B: Testicular tissue from a Stanozolol-treated rat viewed at ten-times magnification.

ISSN Print: 2790-6485 | ISSN Online : 2790-6477 Open Access

3.3. Histopathological Evaluation of the Epididymis

3.3.1. Control Group

Sections of the control group had the normal duct architecture. A dense collection of mature spermatozoa filled the lumen of the cauda epididymis. The epithelial lining has tall columnar cells that are well defined with stereocilia's (Fig 3.2A).

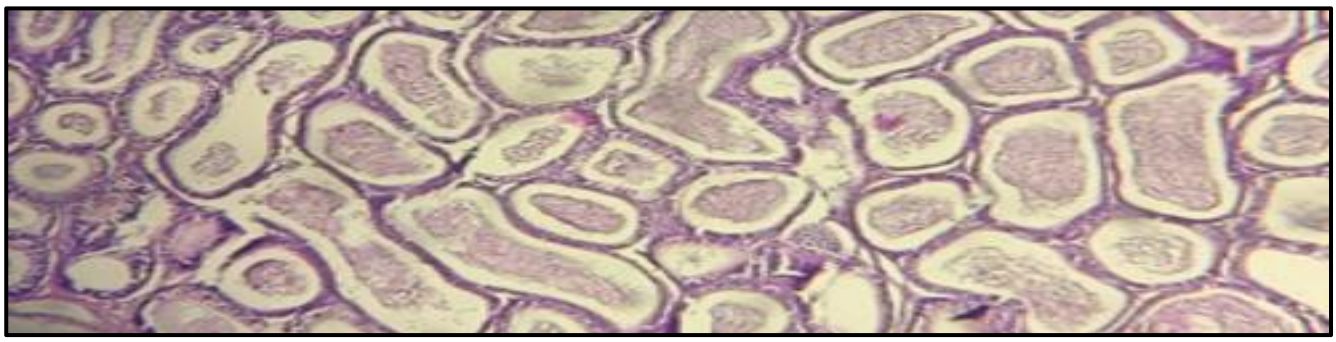

Figure 3.2A: Epididymis of the control group at ten-times magnification.

3.3.2. Stanozolol-Treated Group

Epididymis of rats treated with Stanozolol showed reduction in reproductive function. The lumen contained fewer spermatozoa shows oligospermia compared with the control. The epithelial lining was thinner and there is loss of stereocilia at some sites. In the epididymal lumen there were exfoliated immature germ cells which also suggest an impairment of spermatogenesis within the testes (Figure 3.2B).

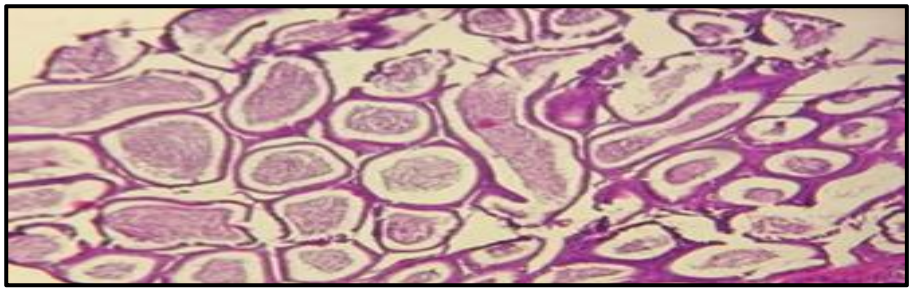

Figure 3.2 B Epididymis of treated animals. Magnification power 10X.

3.4. Histomorphometry Analysis (Quantitative Results)

The microscopic observations were aided by qualitative analysis. The group that was treated with Stanozolol displayed a significant decrease ($p \leq 0.05$) in the diameter of seminiferous tubules, height of germinal epithelium, and Johnsen's mean score. Johnsen's score reduced from 9.5 in the control group to 5.2 in experimental group which means marked damage to spermatogenesis.

Discussion

The present study indicates that eight weeks of Stanozolol application caused obvious histological and morphometric damage in the testicular tissue as well as body growth and skin condition. These conclusions endorse the concept that anabolic-androgenic steroids function as endocrine disruptors, which interferes with normal hormonal regulation (ElShebiney et al., 2025; Albano et al., 2021).

4.1. Effects on Body Weight and Muscle Mass

Stanozolol has anabolic properties, as treated rats showed a marked increase in total body weight. The medication interacts with androgen receptors found in skeletal muscles. This promotes protein synthesis and the retention of nitrogen. (Bento-Silva et al., 2010; Wenbo & Yan, 2023) Even with such an increase in body mass the treated animals presented obvious gonadal atrophy, also termed as the anabolic–genital paradox (Russo et al., 2021;

ISSN Print: 2790-6485 | ISSN Online : 2790-6477 Open Access

Christou et al., 2017). It would appear that the increase in weight is not due to a gain in physiological health, as previously suggested, but rather muscle fiber hypertrophy. Moreover, previous studies suggest that the animal also undergoes metabolic stress that targets organs such as the liver and kidneys (Sessa et al., 2018; Frati et al., 2015).

4.2. Alopecia and Integumentary Effects

Rats treated with Stanozolol experienced focal hair loss and poorer hair quality. Stanozolol, a dihydrotestosterone-derived compound, has a high affinity for androgen receptors in hair follicles, which explains its effects (Sessa et al., 2018). When these receptors are activated, the standard hair growth cycle is shortened by a premature change in the phase of follicles from anagen to telogen. When this process continues over a period of time it leads to follicular miniaturization and hair loss (Margo et al., 2022; Perry et al., 2017). The alterations in the observed animal model result in changes similar to androgen-dependent alopecia of human anabolic steroid users (Amory et al., 2005; Ganesan et al., 2023).

4.3. Testicular Histological and Morphometric Alterations

Morphometric analysis revealed a significant decrease in tubule diameter and germinal epithelial height. The shutdown of this system is due to Stanozolol that offers powerful negative feedback to lessen the release of GnRH, luteinizing hormone, and follicle-stimulating hormone (Al-Otaibi, 2024; Karila et al., 2004). Reduced levels of luteinizing hormone adversely affect Leydig cell function. On the other hand, reduced levels of follicle-stimulating hormone, adversely affect the support provided by Sertoli cells to spermatogenesis (Moss et al., 2022; Nieschlag & Vorona, 2015).

The early-stage blockage of spermatogenesis could also be due to low local testosterone concentrations in the tests that are needed for spermatocyte maturation into spermatids (Shokri et al., 2010; Takahashi et al., 2004). Moreover, the germinal epithelium's vacuolation in the cytoplasm may indicate the disruption of blood–testis barrier, which can expose germ cells to oxidative stress and immune-mediated damage (Pomara et al., 2015; White et al., 2016).

4.4. Oxidative Stress and Apoptosis

The findings agreed with earlier studies that demonstrated Stanozolol increases the production of reactive oxygen species, which can damage the membranes and DNA of germ cells (Albano et al., 2021; Shokri et al., 2014). The treated group showed a lower Johnsen's score and higher apoptosis in the treated group due this oxidative stress (Chimento et al., 2012; Koohi et al., 2011).

4.5. Epididymal Alterations and Sperm Quality

Examination of epididymis exhibited oligospermia and presence of cellular debris within the lumen. This indicates impaired testicular function because normal epididymal functioning is due to testosterone levels originating from the testes (Hijazi et al., 2012; Sullivan & Saez, 2013). A marked decrease or absence of mature spermatozoa in the cauda epididymis explains the infertility seen in long-term anabolic steroid users (Nieschlag, 2014; de Souza & Hallak, 2011).

5 . Conclusions and Recommendations

5.1. Conclusions

The results of this study showed that long-term use of Stanozolol causes significant structural and functional damage to the male reproductive system. Repeated long-term exposure to this anabolic-androgenic steroid has been shown to cause significant damage to the testicular architecture or micromorphology in animals. The seminiferous tubules exhibited severe atrophy and loss of normal architecture along with degeneration of the germinal epithelium thus prolonged use of Stanozolol does compromise testis.

Spermatogenesis was largely affected in treated animals. The investigation revealed the arrest of sperm development at earlier stages, resulting in almost a total absence of mature spermatids and functional spermatozoa. A suppression of the hypothalamic–pituitary–gonadal axis and intratesticular testosterone levels are essential for germ cell maturation. The results of quantitative histomorphometric studies confirmed the

ISSN Print: 2790-6485 | ISSN Online : 2790-6477 Open Access

aforementioned observation by exhibiting drastic reduction in diameter of seminiferous tubules and height of germinal epithelium. This indicates a huge loss of active spermatogenic tissue.

Stanozolol produces strong increases in both body weight and muscle mass but is associated with degeneration of reproductive tissues. This shows that there is a metabolic and reproductive imbalance allowing systemic anabolic growth along with damaging effects on the testes and on the integumentary structures (such as hair follicles). The noted loss of hair further substantiates androgenic stress from prolonged steroid exposure.

Moreover, epididymis structural changes were also noticed in the studies. The semen content in the epididymal lumen diminished due to a noticeable accumulation of cellular debris. Impaired sperm production and transport lead to the reduced male fertility, aided by an accumulation of cellular debris. Ultimately, the extended use of Stanozolol was proven to produce reproductive toxicity, highlighting the reproductive toxicity of anabolic steroids.

5.2. Recommendations

1. Regulatory and Educational Measures:

It is suggested that regulations should be stricter on the distribution of anabolic-androgenic steroids along with more education programs for the public on the irreversible effects of these steroids on one's male fertility, as well as hair and skin. It may reduce non-medical misuse if the risks are communicated clearly.

2. Recovery and withdrawal studies:

Future experimental investigations should take up the post-treatment withdrawal period of study. It should check whether the histological and morphometric changes brought by chronic Stanozolol exposure are reversible or not.

3. Molecular Studies Have Advanced

Future studies should examine the expression of apoptotic markers such as Bax and Bcl-2. The process might shed light on the molecular mechanisms of germ cell death and spermatogenic arrest caused by steroids.

4. Measures meant for protection and prevention.

Research should evaluate the efficacy of antioxidant agents such as Coenzyme Q10, zinc to be used in case of steroid indication to reduce oxidative stress and limit tissue damage.

References

1. Albano, G. D., et al. (2021). Adverse Effects of Anabolic-Androgenic Steroids: A Literature Review. *Healthcare*, 9(1), 97.
2. Al-Otaibi, A. M. (2024). Therapeutic effects of vitamin B17 against anabolic steroid induced testicular toxicity and DNA damage in male rats. *Toxicology Research*, 13(1).
3. Amory, J. K., et al. (2005). The effect of 5α-reductase inhibition on hair loss and androgenic levels. *Journal of Clinical Endocrinology & Metabolism*.
4. AVMA Guidelines. (2020). *AVMA Guidelines for the Euthanasia of Animals: 2020 Edition*.
5. Bento-Silva, M. T., et al. (2010). Effects of Stanozolol on body weight and organ morphology in rats. *Brazilian Journal of Pharmaceutical Sciences*, 46(1).
6. Chimento, A., et al. (2012). Nandrolone and stanozolol induce Leydig cell apoptosis through oxidative stress. *Journal of Molecular Endocrinology*, 48(3).
7. Christou, M. A., et al. (2017). Effects of Anabolic Androgenic Steroids on the Reproductive System of Athletes. *Sports Medicine*, 47(9).
8. de Souza, G. L., & Hallak, J. (2011). Anabolic steroids and male infertility: a comprehensive review. *Clinics*, 66(11).
9. ElShebiney, S. A., et al. (2025). Chronic stanozolol exposure and histological alterations in rat testes. *Journal of Experimental Zoology*.
10. Field, A. (2013). *Discovering Statistics Using IBM SPSS Statistics*. SAGE Publications.
11. Frati, P., et al. (2015). Anabolic Androgenic Steroids (AAS) related deaths: autoptic, histopathological and toxicological findings. *Current Neuropharmaceuticals*, 13(1).
12. Ganesan, K., et al. (2023). Androgenetic Alopecia and Steroid Misuse. *StatPearls Publishing*.

ISSN Print: 2790-6485 | ISSN Online : 2790-6477 Open Access

13. Hashim, N., & Thanoon, I. (2022). Hormonal regulation of the HPG axis and male fertility. *Journal of Reproductive Health*.
14. Hijazi, M. M., et al. (2012). Morphological effects of AAS on testicular structures of Albino Rats. *CABI Digital Library*.
15. Johnsen, S. G. (1970). Testicular biopsy score count—a method for registration of spermatogenesis. *Hormones*, 1(1).
16. Karila, T., et al. (2004). Anabolic androgenic steroids produce dose-dependent inhibition of the HPG axis. *Metabolism*, 53(10).
17. Kilkenny, C., et al. (2010). Improving bioscience research reporting: The ARRIVE guidelines. *PLoS Biology*, 8(6).
18. Margo, K., et al. (2022). Impact of exogenous substances on hormonal feedback mechanisms. *Endocrine Reviews*.
19. Moss, J. L., et al. (2022). Leydig cell function and androgen synthesis in spermatogenesis. *Fertility and Sterility*.
20. National Research Council. (2011). *Guide for the Care and Use of Laboratory Animals*. National Academies Press.
21. Nieschlag, E., & Vorona, E. (2015). Mechanisms of androgen abuse and its effect on the HPG axis. *Molecular and Cellular Endocrinology*.
22. Perry, P. J., et al. (2017). Chronic exposure to external hormonal compounds and reproductive dysfunction. *Journal of Clinical Endocrinology & Metabolism*.
23. Pomara, C., et al. (2015). Metabolic and vascular changes in AAS users. *Current Medicinal Chemistry*, 22(1).
24. Russo, G. I., et al. (2021). Clinical and subclinical effects of AAS on the male reproductive system. *Andrology*, 9(1).
25. Salerno, M., et al. (2018). Anabolic androgenic steroids and carcinogenicity focusing on Leydig cell. *Oncotarget*, 9(27).
26. Sessa, F., et al. (2018). Anabolic Androgenic Steroids: Analysis of Side Effects on the integumentary system. *Recent Patents on Inflammation & Allergy Drug Discovery*.
27. Z J Naqi, W H Yahya, A K Abdulhussain , B A Nasir. (2025). A study of The effect of Alcoholic Extract of Celery Seeds on The Concentration of Sex Hormones in Male White Rats Treated with Depakine., Al-Harf Journal., No. 24., Vol. 1, March 2025
28. Shokri, S., et al. (2010). Exercise and high dose Stanozolol on apoptosis and spermatogenesis in rats. *Andrologia*, 42(6).
29. Shokri, S., et al. (2014). Effects of Stanozolol on DNA fragmentation of germ cells. *Cell Journal*.
30. Sullivan, R., & Saez, F. (2013). Epididymal markers of sperm quality. *Asian Journal of Andrology*.
31. Suvarna, S. K., et al. (2018). *Bancroft's Theory and Practice of Histological Techniques*. Elsevier.
32. Takahashi, M., et al. (2004). Adverse effects of anabolic steroids on reproductive organs. *Journal of Toxicological Sciences*, 29(1).
33. Wenbo, Z., & Yan, Z. (2023). The Uses of Anabolic Androgenic Steroids Among Athletes. *Journal of Multidisciplinary Healthcare*, 16.
34. White, J., et al. (2016). Toxicological reports on synthetic androgen induced testicular damage. *Toxicology Reports*.