Kuwait Research Journal of Agriculture and Life Science (KRJALS)

ISSN Print: 2790-6485 | ISSN Online : 2790-6477 Open Access

The Effect of Paracetamol on the Occurrence of Fetal Malformations in Rats

Nawras Ali Hussein Al-jubouri[1] , Zahraa Hussein Abdulateef [2] , Atheer Hasan Atiyah[3]
[1]Lecturer, Al-Furat Al-Awsat Technical University, Najaf Technical Institute, Iraq.
[2]Assist. Lecturer, Al-Furat Al-Awsat Technical University, Najaf Technical Institute, Iraq.
[3]Assist. Lecturer, Al-Furat Al-Awsat Technical University, Najaf Technical Institute, Iraq.

*Corresponding Author

Nawras Ali Hussein Al-jubouri
Lecturer, Al-Furat Al-Awsat Technical University, Najaf Technical Institute, Iraq.

Article History
Received: 02.12.2025
Revise : 10.01.2026
Accepted: 14.01.2026
Published: 17.01.2026

DOI:10.61705/KRJALS.5.1.2026.01.11

Keywords: Acetaminophen, Fetal malformations, Fetal skeleton, Paracetamol, Pregnancy.

Abstract:
Paracetamol, also known as acetaminophen, is one of the most widely used medications worldwide for pain relief and fever reduction., Aim of the Work: The aim of this study is to determine the effect and ability of paracetamol to cause fetal malformations in pregnant rats., Materials and Methods: The study included (36) of pregnant rats, divided into three groups, the first group doses the set of control with distilled water only, the second group doses the drug of paracetamol 250 mg/kg, the third group died with the drug paracetamol 350 mg/kg of body weight from the first day to twenty days of pregnancy., Results: The results of the current study showed that the length of the skull, vertebral column, front limbs, and hind limbs of fetuses at 20 days of gestation from the group treated with paracetamol at doses of 250 and 350 mg/kg of body weight showed a significant decrease ($P<0.05$) compared to the control group. The results of the statistical analysis showed a significant decrease ($P<0.05$) in calcium, phosphorus, sodium and potassium concentration in the two groups of pregnant mothers treated with paracetamol 250 and 350 mg/kg at the stages of pregnancy (10, 15 and 20) compared to the control group. Histological examination of the kidneys of newborns treated with paracetamol 250 and 350 mg/kg immediately after birth showed clear pathological effects compared with the control group., Conclusion: The results indicate that paracetamol is unsafe for use during pregnancy.

Introduction

Congenital malformations are disorders resulting from genetic and/or developmental abnormalities that occur during the fetal stage. They are classified within a broad spectrum of structural, functional, metabolic, and behavioral abnormalities. They are also known by terms such as birth defects or congenital disorders. These conditions are present at birth and are often associated with high rates of morbidity and mortality, particularly during the neonatal and infancy periods. Their etiology is attributed to a complex interaction of genetic and environmental factors, including physical (such as radiation), chemical (such as certain drugs and toxic substances), and biological (such as viral infections during pregnancy) [1].

Congenital malformations are structural or functional defects that arise during fetal life and are present at birth. They can affect any body system and range in severity from mild to complex. Children born with congenital malformations who survive often face long-term health challenges, including physical, psychological, and cognitive impairments. Globally, the incidence of congenital malformations is estimated to range from 2% to 4% of all births. Data indicate that the rates of

ISSN Print: 2790-6485 | ISSN Online : 2790-6477 Open Access

these cases in Arab countries are higher than in other countries, as reported in some studies [2]. The 2013 Global Burden of Disease Study ranked congenital malformations among the top ten leading causes of death in children under five years of age [3]. In 2016, approximately 303,000 babies were born with congenital malformations, according to reports from the World Health Organization. The incidence of these malformations is estimated at approximately 3 cases per 1,000 live births, with the total number likely reaching approximately 99 million births annually worldwide [4].

The Global Burden of Disease Study showed that congenital malformations were the cause of approximately 510,400 deaths worldwide in 2010 [5]. These malformations affect approximately 1 in 33 births, causing approximately 6.6% of infant deaths and serious childhood health complications. According to World Health Organization estimates, approximately 3 million fetuses and newborns are born with severe congenital malformations each year. These malformations are a leading cause of neonatal mortality, contributing to approximately 495,000 deaths annually, most of which occur during the first year of life, increasing child mortality rates. Major population-based studies indicate that major congenital malformations affect 2–3% of all live births and account for 15–30% of pediatric hospitalizations. They also require more healthcare resources than most other conditions, placing a significant burden on communities and families in particular [6].

More than 90% of children with dangerous congenital malformations are born in middle- or low-income countries, while higher rates of these malformations are recorded in Arab countries compared to other non-Arab countries [4]. However, documentation of birth defects in many developing countries remains inaccurate or insufficient [7]. The rates and patterns of congenital malformations vary across geographic regions, and many factors have been analyzed, including genetic factors, environmental factors causing malformations, micronutrient deficiencies, and multifactorial inheritance. Common risk factors include drug abuse, advanced maternal age, alcohol consumption, consanguineous marriage, smoking, and certain maternal diseases. Although these malformations may result from a single factor or a combination of genetic, nutritional, environmental, or infectious factors, pinpointing the exact cause is often difficult. It is estimated that approximately 60–70% of cases are attributable to unknown causes [8].

Congenital malformations have long been known and recognized, and due to their high incidence, the clarity of their symptoms, and their profound impact on the patient and his family, they have become a topic of interest to researchers and a stimulus for their study [9].

Acetaminophen is a medication used to relieve pain and reduce fever and is available without a prescription. It is different from other over-the-counter pain relievers, such as ibuprofen and naproxen, although they are used for the same purposes as pain and fever. Acetaminophen is widely used in both children and adults and is available in several dosage forms, including tablets, syrup, injections, and suppositories. Outside of Canada and the United States, this medication is known as "paracetamol" and is used for the same purposes [10].

Paracetamol has no anti-inflammatory effect in rheumatic disorders, but it is considered safer than aspirin, as it does not cause anemia or liver damage, complications that can occur with chronic use of acetanilide or acetophenetidin. Paracetamol is commonly used to reduce fever, relieve joint and muscle pain, alleviate symptoms of colds and flu, and relieve common headaches [11].

Materials and Methods

In this experiment, paracetamol was used as the active compound to study its effect

Paracetamol tablets of 500 mg each were bought from a local pharmacy in Najaf Governorate, Iraq, for experimental use within the current study.

laboratory animals

Thirty-six female and ten male albino rats, three months old, were obtained from the College of Veterinary Medicine, University of Kufa, weighing 180-240 g. The animals were maintained under controlled environmental

ISSN Print: 2790-6485 | ISSN Online : 2790-6477 Open Access

conditions, including a regular light cycle (12 h light and 12 h dark) and a constant temperature of 25°C. Sufficient amounts of food and water were provided ad libitum throughout the experimental period. The animals underwent a two-week acclimatization period before the start of the experiment to ensure that they adapted to the new environment and were free of any diseases or pregnancy. Two sexually mature female rats were placed in a cage with a sexually mature male overnight. Mating was confirmed by observing the presence of sperm from the male in a vaginal smear or by detecting a vaginal plug. The day on which sperm appeared in the vaginal smear or on which the vaginal plug was detected was considered day 0 of pregnancy, and the following day was considered day 1 of pregnancy. The animals were divided into three groups: -

Group 1

The study included a group of twelve pregnant female rats. This group was assigned to receive only distilled water, orally via a feeding tube, starting on the first day of pregnancy confirmation (determined by the presence of a vaginal plug or semen in a vaginal smear). Distilled water administration continued daily until the twentieth day of pregnancy. At the end of this period, the animals were euthanized in accordance with ethical research procedures for testing. Three of the animals were left to give birth. This group served as a negative control, as they were not exposed to any active substance or experimental intervention.

Group 2

The group consisted of 12 pregnant female rats, which were given an oral dose of 250 mg/kg of paracetamol from the first day of pregnancy until the end of the experimental period. These rats were euthanized on the 20th day of pregnancy for the study, and three were left to give birth.

Group 3

The group consisted of 12 pregnant female rats, which were given an oral dose of 350 mg/kg of paracetamol from the first day of pregnancy until the end of the experimental period. These rats were euthanized on the 20th day of pregnancy for the study, and three were left to give birth.

Blood was drawn from pregnant mothers from the control group and the drug-treated groups at 10, 15 and 20 days of pregnancy.

Dissection of Pregnant Rats and Blood Collection

The day after the end of the dosing cycle and the final dose was administered to all groups, the animals were anesthetized with a mixture of xylazine (0.6) and ketamine (0.4) in a total ratio of (1 ml), equivalent to (0.2) per animal. After anesthesia, the animals were fixed to the dissection plate using pins, and a blood sample was drawn directly from the heart using the heart puncture technique to obtain the largest possible amount, approximately (5) ml. The samples were placed in anticoagulant-free gel tubes and left at laboratory temperature for (10) minutes. Afterwards, the serum was centrifuged to separate the serum, and then the serum was transferred to clean, sterile test tubes and kept at (20) °C until the required biochemical tests were performed within the study.

The abdominal cavity of 20-day-old pregnant female rats was opened, and the two uterine horns containing the fetuses were extracted. Microdissection tools were then used to carefully remove the fetal membranes, followed by anesthetizing six of these fetuses with a sufficient amount of diethyl ether.

Preparing The fetal skeleton

After obtaining embryos at 20 days of gestation from the control and other treated groups, six embryos were selected for study of skeletal abnormalities. These embryos underwent a process of translucency and staining of their skeletons to analyze skeletal defects, using the method described by [12].

1. (6)embryos were immersed in clean glass containers containing a 1% potassium hydroxide (KOH) solution.
2.The 1% potassium hydroxide solution was changed daily until the sticky substance surrounding the animal skeletons was removed.
3.The skeletons were immersed in glass containers containing freshly prepared potassium hydroxide solution.
4.Add 1-2 drops of alizarin red dye (Alizarin Red S) to each container.
5.The containers containing the animals were

ISSN Print: 2790-6485 | ISSN Online : 2790-6477 Open Access

left until the next day.
6.If the skeletons were well stained, the solution containing the skeletons and the dye was replaced with 50% glycerol and the containers were left until the next day.
7.If the skeletons were not well stained, the step of adding the dye to the containers and the subsequent steps were repeated.
8.Then, the 50% glycerol solution was replaced with a 100% concentrated glycerol solution.
9.Store containers containing stained skeletons in a dark place while they are being examined.

Biochemical Tests

Measuring the concentration of calcium ions in the serum

Serum calcium ion concentration was determined using a ready-to-use test kit from SPINREACT, using a colorimetric method according to [13]. This method is based on the reaction of calcium ions with the reagent O-Cresol phthalein in a basic medium, leading to the formation of a color complex that can be measured spectrophotometrically. The intensity of the color complex formation is a direct indicator of the calcium ion concentration in the sample, as it is directly proportional to the amount of calcium present.

$$Ca + \text{O-Cresolphtalein} \xrightarrow{OH} \text{Colored Complex}$$

Measuring the concentration of phosphorus in the serum

The colorimetric method was used to estimate the phosphorus concentration [14].

Measuring serum sodium concentration in the serum

The ready-made test kit was used to measure the sodium concentration in blood serum. The sodium concentration in blood serum is estimated by a colorimetric method [15].

Measure the concentration of potassium in the serum

A ready-made test kit was used to measure serum potassium concentration.

$$\text{Na-Tetraphenylborate} + K^+ \longrightarrow \text{K-Tetraphenylborate} + Na^+$$

The potassium concentration was estimated using the turbidity method, as the turbidity range is proportional to the potassium concentration. The absorbance was measured at a wavelength of 570-578 nm [16].

Histological Examination

Histological sections of kidneys from the control and paracetamol-treated groups were prepared immediately after birth according to method [17]. The samples passed through eight stages (fixation, dehydration, clearing, infiltration, embedding, sectioning, staining, mounting and covering).

Statistical Analysis

A two-way ANOVA analysis was conducted to study the effect of paracetamol on biochemical parameters in pregnant female rats, and to test the significance of differences between means using the modified Duncan test. The Revised Least Significant Differences (L.S.D.) was used at a significance level of 0.05 ($P>0.05$) [18].

Results and Discussion

The effect of paracetamol on the skeleton of rat fetuses on the twentieth day of pregnancy

The results of the examination of the skeletal structures of fetuses whose mothers were treated with paracetamol at doses of 250 and 350 mg/kg showed that the bones of the fetuses in the control group acquired a redder color with alizarin red staining than those in the fetuses treated with paracetamol, indicating the advancement of the ossification process in the fetal skeleton, as shown in (Figure 1).

Kuwait Research Journal of Agriculture
and Life Science (KRJALS)

ISSN Print: 2790-6485 | ISSN Online : 2790-6477 Open Access



Fig. 1. Three fetuses at twenty days of gestation: a fetus from the control group (C), a fetus from the group treated with the drug 250 mg/kg body weight (T1), and a fetus from the group treated with the drug 350 mg/kg body weight (T2). The skull (S), ribs (Rb), vertebral column (VC), forelimbs (FL), and hindlimbs (RL).

The results of the current study also showed that the length of the skull, spine, forelimbs, and hindlimbs of fetuses at 20 days of pregnancy in the group treated with paracetamol at doses of 250 and 350 mg/kg of body weight decreased significantly ($P<0.05$) compared to the control group, as shown in (Figure 2). These results are consistent with what was found by [19] when he dosed female rats with ochratoxin-A once a day from 7 to 14 days of pregnancy at a concentration of 1 mg/kg and 2 mg/kg. This may be due to the toxic effect of the drug on cell division and embryo formation, which leads to inhibition of the growth of skeletal structures, especially in the studied areas (skull, spine, and limbs). Paracetamol may also inhibit the enzyme cyclooxygenase, which reduces the production of prostaglandins, which are important for the perfusion of growing tissues, leading to a lack of oxygen reaching the bones. It may also be due to the oxidative stress of the drug and the production of toxic substances. In the liver and its transfer through the placenta to the fetal tissues such as bones, which affect bone cells.

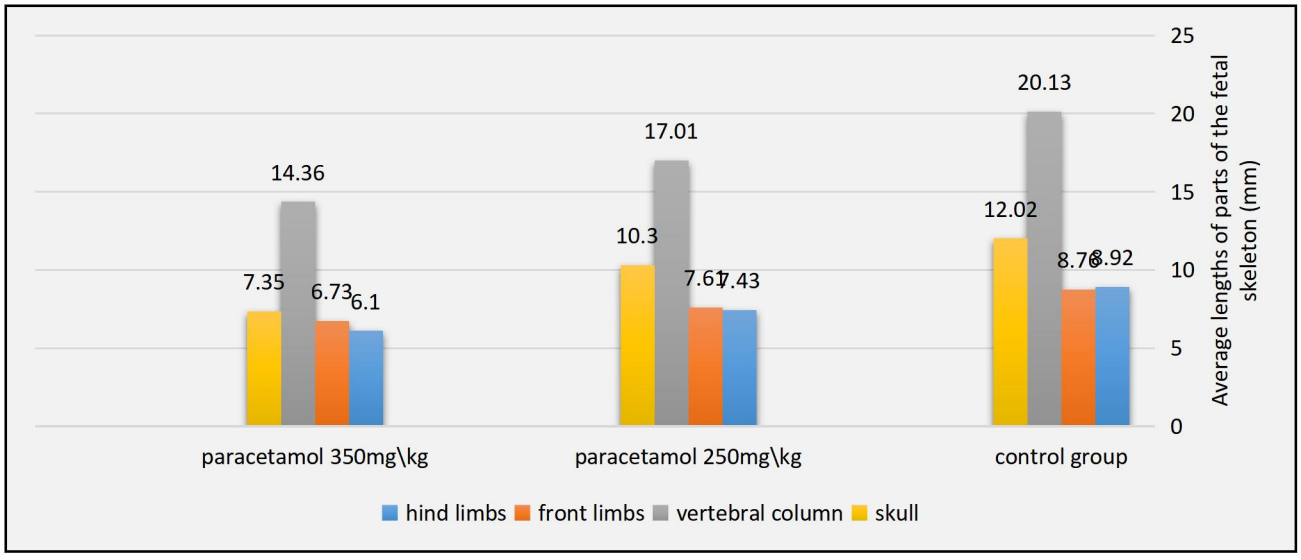

Fig. 2. The effect of paracetamol on the length of parts of the skeleton (mm) of the fetus at 20 days of pregnancy

ISSN Print: 2790-6485 | ISSN Online : 2790-6477 Open Access

The effect of paracetamol on blood electrolyte concentrations in pregnant female rats.

The results of the statistical analysis of the current study showed a significant decrease (P<0.05) in (calcium, phosphorus, sodium, potassium) concentration in the two groups of pregnant mothers treated with paracetamol 250 and 350 mg/kg at the stages of pregnancy (10, 15 and 20) compared to the control group as shown in Table 1, Table 2, Table 3, Table 4. This study was partially consistent with [20] who injected a group of rats with 100 mg/kg of body weight paracetamol for three days, as well as the study [21] who dosed a group of rats with 500 mg/kg of body weight paracetamol. The reason behind the significant decrease in electrolytes may be due to the increase in oxidative stress and the production of free radicals in the body caused by the drug, which leads to a defect in the liver and kidney cells, which may weaken the regulation of mineral balance. The reason may be due to the drug negatively affecting the absorption of calcium and phosphorus in the digestive system, or the reason may be due to the effect of paracetamol on the secretion of aldosterone, cortisol, or renin, which causes a defect in the absorption and reabsorption of sodium and potassium in the kidneys, or increased excretion of electrolytes through urine.

Table 1. Effect of paracetamol on calcium concentration (mmol/l) in the blood serum of pregnant female rats.

	Control group	**250 mg/kg oral dose of paracetamol**	**350 mg/kg oral dose of paracetamol**	**Average duration**
10 days of pregnancy	0.91±0.023 a A	0.88±0.037 a B	0.83±0.025 a C	0.87±0.011 a
15 days of pregnancy	0.87±0.021 b A	0.80±0.023 b B	0.74±0.030 b C	0.80±0.009 b
20 days of pregnancy	0.71±0.037 c A	0.65±0.020 c B	0.59±0.026 c C	0.65±0.002 c
Average of the groups	0.83±0.022 A	0.77±0.012 B	0.72±0.031 C	

Mean ± standard error n=9
Different lowercase letters indicate significant differences vertically at the (P<0.05) level.
Different capital letters indicate horizontal significant differences at the (P<0.05) level.

Table 2. Effect of paracetamol on phosphorus concentration (mmol/l) in the blood serum of pregnant female rats.

	control group	**250 mg/kg oral dose of paracetamol**	**350 mg/kg oral dose of paracetamol**	**Average duration**
10 days of pregnancy	6.93±0.33 a A	6.71±0.17 a B	6.02±0.39 a C	6.55±0.04 a
15 days of pregnancy	6.51±0.21 b A	6.11±0.25 b B	5.31±0.21 b C	5.97±0.09 b
20 days of pregnancy	6.01±0.29 c A	5.44±0.16 c B	4.94±0.44 c C	5.46±0.17 c
Average of the groups	6.48±0.20 A	6.08±0.31 B	5.42±0.34 C	

ISSN Print: 2790-6485 | ISSN Online : 2790-6477 Open Access

Mean ± standard error n=9
Different lowercase letters indicate significant differences vertically at the (P<0.05) level.
Different capital letters indicate horizontal significant differences at the (P<0.05) level.

Table 3. Effect of paracetamol on sodium concentration (mmol/l) in the blood serum of pregnant female rats.

	Control group	250 mg/kg oral dose of paracetamol	350 mg/kg oral dose of paracetamol	Average duration
10 days of pregnancy	149.5±2.15 a A	140.0±0.32 a B	131.2±1.90 a C	140.2±1.22 a
15 days of pregnancy	143.2±3.06 b A	138.5±1.02 b B	124.6±2.86 b C	135.4±0.66 b
20 days of pregnancy	139.7±2.80 c A	128.1±1.80 c B	116.8±2.27 c C	128.2±0.53 c
Average of the groups	144.1±2.77 A	135.5±1.45 B	124.2±2.44 C	

Mean ± standard error n=9
Different lowercase letters indicate significant differences vertically at the (P<0.05) level.
Different capital letters indicate horizontal significant differences at the (P<0.05) level.

Table 4. Effect of paracetamol on potassium concentration (mmol/l) in the blood serum of pregnant female rats

	control group	250 mg/kg oral dose of paracetamol	350 mg/kg oral dose of paracetamol	Average duration
10 days of pregnancy	6.11±0.31 a A	5.94±0.68 a B	5.34±0.27 a C	5.79±0.07 a
15 days of pregnancy	6.04±0.18 b A	5.75±0.27 b B	5.01±0.33 b C	5.60±0.13 b
20 days of pregnancy	5.98±0.21 c A	5.25±0.33 c B	4.63±0.28 c C	5.28±0.06 c
Average of the groups	6.04±0.37 A	5.64±0.26 B	4.99±0.28 C	

Mean ± standard error n=9
Different lowercase letters indicate significant differences vertically at the (P<0.05) level.
Different capital letters indicate horizontal significant differences at the (P<0.05) level.

Histological examination of the newborn kidney immediately after birth

The results of the current study on the kidneys of newborns treated with paracetamol 250 and 350 mg/kg immediately after birth showed clear pathological effects represented by dilation of Bowman's space and destruction of the wall of Bowman's capsule, shrinkage, degeneration, necrosis, hemorrhage and destruction of the renal glomerulus, severe hemorrhage and necrosis of urinary tissue and tubules, separation of the inner lining of the tubules, destruction of the tubule wall, infiltration of inflammatory cells, and congestion of blood compared to the control group, as shown in (Figure 3, Figure 4, and

ISSN Print: 2790-6485 | ISSN Online : 2790-6477 Open Access

Figure 5). The reason may be oxidative stress resulting from the formation of oxygen free radicals during paracetamol treatment within the mitochondria, which is a source of generating oxygen free radicals in the cell, as the drugs work to dismantle and inhibit oxidative phosphorylation in them inside and outside the living body, causing a malfunction in their function and consequently a decrease in the energy produced inside the cell (ATP) and an increase in the formation of oxygen free radicals, which is a catalyst for the destruction of cells and tissues in the urinary system due to the loss of balance between oxidizing agents and antioxidants. This is what [22] . This study was consistent with [23] , where male rabbits were given a dose of paracetamol at a concentration of 400 mg/kg for four weeks. The researcher [24] reached the same result when he dosed mice with ivabradine at concentrations of 20 mg/kg and 40 mg/kg of body weight.

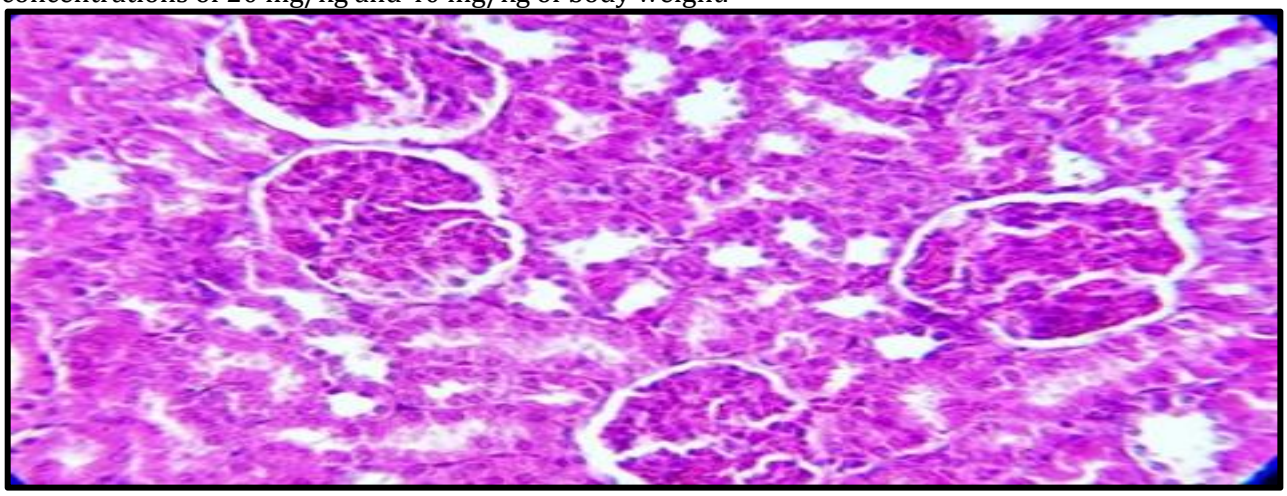

Fig. 3. A cross section of the renal cortex of a newborn from the control group immediately after birth, showing: Bowman's capsule space, Bowman's capsule wall, renal glomerulus, and urinary tubule (hematoxylin-eosin 400x).

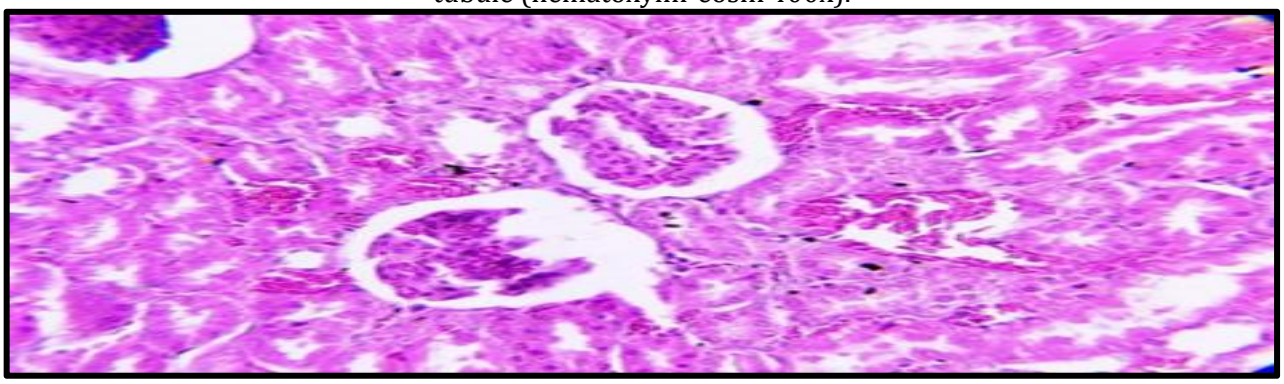

Fig. 4. A cross section of the renal cortex of a newborn immediately after birth from the group treated with paracetamol 250 mg/kg showing: congestion, tubular hemorrhage, dilatation of the Bowman's capsule space, and shrinkage of the renal glomerulus (hematoxylin-eosin 400x).

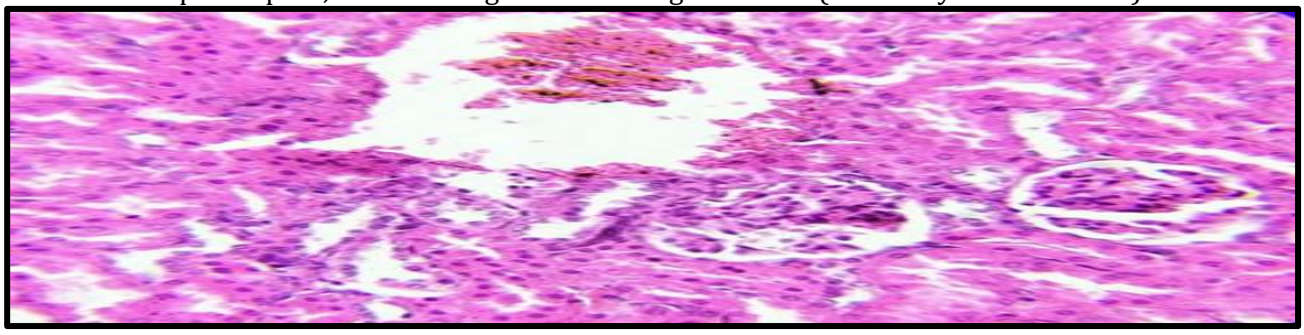

Fig. 5. A cross section of the renal cortex of a newborn immediately after birth from the group

ISSN Print: 2790-6485 | ISSN Online : 2790-6477 Open Access

treated with paracetamol 350 mg/kg. It shows: necrosis and hemorrhage in the interstitial connective tissue of
the cortex, infiltration of inflammatory cells, and necrosis of the renal glomerulus (hematoxylin-eosin 400x).

Conclusion

This current work was partially regular with that injected a group of rats with 100 mg/kg of body weight paracetamol for three days, as well as the study that dosed a group of rats with 500 mg/kg of body weight paracetamol. The reason behind the significant decrease in electrolytes may be due to the increase in oxidative stress and the production of free radicals in the body caused by the drug, which leads to a defect in the liver and kidney cells, which may weaken the regulation of mineral balance. Paracetamol caused pathological changes in blood parameters in pregnant rats during pregnancy and in the kidney tissue of newborns and distorted the fetal skeleton. Therefore, the use of this drug should be limited during pregnancy.

Acknowledgment

I would like to extend my sincere thanks and gratitude to my dear husband, Karar Saad Yassin, for his continuous moral support and encouragement, as well as his invaluable assistance, which played a significant role in the completion of this research and its proper production. Without his support and dedication, this effort would not have been possible. He has my deepest gratitude and prayers for continued success.

References

1. Leibovitz Z, Lerman-Sagie T, Haddad L. Fetal brain development: regulating processes and related malformations. Life. 2022 May 29;12(6):809. https://doi.org/10.3390/life12060809
2. Kamal Helmy H, Ibrahim Ali Ibrahim S, Ezzat Mahmoud O, Arafat Goda A. Effect of Antenatal Nursing Interventions on Knowledge, Attitudes and Coping Strategies of Pregnant Women who Detected Fetal Anomalies regarding Congenital Anomalies. Egypt. J. Health Care. 2021 Sep 1;12(3):131-45.
3. Kang L, Cao G, Jing W, Liu J, Liu M. Global, regional, and national incidence and mortality of congenital birth defects from 1990 to 2019. Eur. J. Pediatr. 2023 Apr;182(4):1781-92. https://doi.org/10.1007/s00431-023-04865-w
4. Gedamu S, Sendo EG, Daba W. Congenital anomalies and associated factors among newborns in Bishoftu General Hospital, Oromia, Ethiopia: a retrospective study. J. Environ. public health. 2021;2021(1):2426891. https://doi.org/10.1155/2021/2426891
5. Lee KS, Choi YJ, Cho J, Lee H, Lee H, Park SJ, Park JS, Hong YC. Environmental and genetic risk factors of congenital anomalies: an umbrella review of systematic reviews and meta-analyses. J Korean Med Sci. 2021 Jul 19;36(28). DOI: https://doi.org/10.3346/jkms.2021.36.e183
6. Banu T, Sharma S, Chowdhury TK, Aziz TT, Martin B, Seyi-Olajide JO, Ameh E, Ozgediz D, Lakhoo K, Bickler SW, Meara JG. Surgically correctable congenital anomalies: reducing morbidity and mortality in the first 8000 days of life. World J Surg. 2023 Dec;47(12):3408-18. https://doi.org/10.1007/s00268-023-07087-1
7. Malherbe HL, Modell B, Blencowe H, Strong KL, Aldous C. A review of key terminology and definitions used for birth defects globally. J community Genet. 2023 Jun;14(3):241-62. https://doi.org/10.1007/s12687-023-00642-2
8. Agot GN, Mweu MM, Wang'ombe JK. Risk factors for major external structural birth defects among children in Kiambu County, Kenya: a case-control study. F1000Res. 2021 Apr 30;10:59. https://doi.org/10.12688/f1000research.50738.2
9. Hantoushzadeh S, Geran Orimi T, Zarkesh MR, Geran Orimi T. Neonatal Multisystem Inflammatory Syndrome Consequent to

ISSN Print: 2790-6485 | ISSN Online : 2790-6477 Open Access

Perinatal SARS-COVID-2-Infection: A Narrative Review Study. J Obstet, Gynecol Cancer Res. 2022 Sep 9;7(6):471-8. https://doi.org/10.30699/jogcr.7.6.471

10. Dart RC, Mullins ME, Matoushek T, Ruha AM, Burns MM, Simone K, Beuhler MC, Heard KJ, Mazer-Amirshahi M, Stork CM, Varney SM. Management of acetaminophen poisoning in the US and Canada: a consensus statement. JAMA network open. 2023 Aug 1;6(8):e2327739-. https://doi:10.1001/jamanetworkopen.2023.27739
11. Hatano M, Sasabuchi Y, Ishikura H, Watanabe H, Tanaka T, Tanaka S, Yasunaga H. Outcomes after hip fracture surgery in patients receiving non-steroidal anti-inflammatory drugs alone, acetaminophen alone, or both: a nationwide retrospective cohort study. Bone Joint J. 2024 Aug 1;106(8):849-57. https://doi.org/10.1302/0301-620X.106B8.BJJ-2024-0183.R1
12. Booth M, Powell N, Corfield C, French JM. An automated technique for double staining of bone and cartilage in fetal mouse skeletal specimens using alizarin red S and Alcian blue. Biotech Histochem. 2022 Apr 3;97(3):222-7. https://doi.org/10.1080/10520295.2021.1933179
13. Tarara M, Tzanavaras PD, Tsogas GZ. Development of a paper-based analytical method for the colorimetric determination of calcium in saliva samples. Sensors. 2022 Dec 24;23(1):198. https://doi.org/10.3390/s23010198
14. McGhee MF, Saxelby CA, McKay N. A guide to laboratory investigations. CRC Press; 2021 Nov 15. https://doi.org/10.1201/9781003049685
15. Young DS. Effects of drugs on clinical laboratory tests. Ann clin Biochem. 1997 Nov;34(6):579-81. https://doi.org/10.1177/000456329703400601
16. Bishop ML. Clinical chemistry: Principles, techniques, and correlations, enhanced edition: Principles, techniques, and correlations. Jones & Bartlett Learning; 2020 Jun 11. https://books.google.iq/url?id=VTXsDwAAQBAJ&pg=PP1&q=http://www.jblearning.com&linkid=1&usg=AOvVaw1p9-V4mXvqoaTzAnG5XMXh&source=gbs_pub_info_r
17. Suvarna KS, Layton C, Bancroft JD. Bancroft's theory and practice of histological techniques E-Book. Elsevier health sciences; 2018 Feb 27. https://books.google.iq/url?id=CERPDwAAQBAJ&pg=PP1&q=http://www.us.elsevierhealth.com/&linkid=1&usg=AOvVaw3YxvmRQcH399VqwjEyDRlY&source=gbs_pub_info_r
18. Sammar Faisal J, I Hussein Aziz. (2025). Study Gene Expression Level of MMP14 in Breast Cancer Patients in Iraq., Al-Harf Journal ., No. 24 ., Vol. 4, November 2025
19. Z A A Mousa, S Mahdi A. J. (2025). Evaluation of Routine Hematological Markers as Prognostic Factors in Endometriosis-Associated Ovarian Cancer., Al-Harf Journal., No. 24 .,Vol. 4, November 2025
20. Choi KR, Ryu JY, Lee SY. Revisiting statistical design and analysis in scientific research. Small. 2018 Oct;14(40):1802604. https://doi.org/10.1002/smll.201802604
21. Al-Timimi ZK, Gali MA. Effect of Ochratoxin-A on Mouse Embryos. Baghdad Sci J. 2018;15(1):1. https://doi.org/10.21123/bsj.2018.15.1.0001.
22. Matić MM, Milošević MD, Paunović MG, Ognjanović BI, Štajn AŠ, Saičić Z. Paracetamol-induced changes of haemato-biochemical and oxidative stress parameters in rat blood: protective role of vitamin C and betaglucan. Kragujevac J. Sci. 2016;38:135-46. https://radar.ibiss.bg.ac.rs/handle/123456789/2616
23. Samah A, Fatma A, Osama A. Effects of rosemary oil against hemato-biochemical alterations and renal oxidative damage induced by Paracetamol in rats. Ann. vet anim. sci. 2019:1-7. DOI:10.26609/avas.652
24. S. S Abdul-Hur, S M Jwad, " A physiological, Histological Evaluation Study of Erythropoietin Hormone Levels and some other Biomarkers in Male Albino Rats Treated with Acetaminophen Drug and Alcoholic Extract of Malus domestica Peels",

ISSN Print: 2790-6485 | ISSN Online : 2790-6477 Open Access

Al-Harf Journal, 21(June) 2024.

25. Chaudhary P, Janmeda P, Docea AO, Yeskaliyeva B, Abdull Razis AF, Modu B, Calina D, Sharifi-Rad J. Oxidative stress, free radicals and antioxidants: potential crosstalk in the pathophysiology of human diseases. Front. chem. 2023 May 10;11:1158198. https://doi.org/10.3389/fchem.2023.1158198
26. Al-Basha, Muhammad Umar, Azab, Azab Al-Sayyid, Al-Madihin , Najah Daw . The effect of inhaling gasoline and taking paracetamol, or both, together on the functions and histology of the kidneys in male rabbits. The 1st International Conference of the Faculties of Sciences. 2022 February.
27. Khaleel HK. Investigating the histological changes in heart, lung, liver and kidney of male albino mice treated with Ivabradine. Baghdad Sci J. 2019;16(3):25. https://doi.org/10.21123/bsj.2019.16.3(Suppl.).0719