Kuwait Research Journal of Agriculture and Life Science(KRJALS)

ISSN Print:2790-6485 | ISSN Online : 2790-6477 Open Access

A Study on the Effect of the Antibiotic Ibuprofen on the Histological Structure of the Kidneys in White Rats

Saja. A. Mazher[1], Atyaf. S. Hussein[2] , Zahraa. H. Ali[3]

[1],[2]Assist. Lecturer., Al-Furat Al-Awsat Technical University, Najaf Technical Institute, Department of Forensic Techniques, Iraq.

[3]Assist. Lecturer., Al-Furat Al-Awsat Technical University, Najaf Technical Institute, Department of Aesthetic and Laser Technical , Iraq.

*Corresponding Author

Saja. A. Mazher

Assist. Lecturer., Al-Furat Al-Awsat Technical University, Najaf Technical Institute, Department of Forensic Techniques, Iraq.

Article History

Received: 02.08.2025

Revise : 08.09.2025

Accepted: 12.09.2025

Published: 16.09.2025

DOI:10.61705/KRJALS.4.3.2025.1.7

Keywords: Ibuprofen, Acute glomerulonephritis, Renal histopathology, White rats

Abstract:

The current study aimed to evaluate the histological effects of Ibuprofen on the renal tissue of white laboratory rats. A total of 12 adult white rats were used and randomly divided into two groups, with each group consisting of 6 rats. The animals were administered an injection of the anti-inflammatory drug Ibuprofen at a dose of 30 mg/kg of body weight. Upon completion of the dosing and injection period for all experimental animals, the rats were euthanized and dissected for the purpose of histological examination. The study focused on the urinary system and included a comparison with the control group. Histopathological examination revealed significant renal damage, including acute glomerulonephritis characterized by leukocytic infiltration, epithelial wall thickening. Additional findings included necrosis of glomerular and tubular cells, as well as erythrocyte congestion within the capillaries.

Introduction

The urinary system is one of the essential systems that help to maintain the body's health and homeostasis. The primary function of this system is to cleanse the body of waste products and excess fluids through the formation of urine. The urinary system consists of the kidneys, ureters, urinary bladder, and urethra (1). The kidneys are the most important components of this system, as they filter the blood, remove harmful substances, and regulate the balance of water, electrolytes, and pH in the body. In addition, the kidneys play a vital role in regulating blood pressure and producing essential hormones such as erythropoietin, which stimulates the production of red blood cells (2). The urinary system maintains internal stability of the organism and guarantees the continuous function of critical organs (3).

Antibiotics are among the most significant medical discoveries of the twentieth century, having played a crucial role in combating bacterial infections and limiting the spread of infectious diseases. These compounds act by either killing bacteria or inhibiting their growth, thereby helping the body overcome infections (4). Antibiotics vary in their mechanisms of action and spectrum of activity; some are target against specific bacterial types, while others have a broad-spectrum effect, acting against multiple bacterial species (5). Despite their effectiveness, the misuse of antibiotics can lead to the emergence of antibiotic- resistant bacterial strains, which represents a global health challenge that requires increased awareness and the careful application of

ISSN Print:2790-6485 | ISSN Online : 2790-6477 Open Access

appropriate therapeutic practices (6).

Ibuprofen is one of the commonly used drugs within the class of nonsteroidal anti-inflammatory drugs (NSAIDs). It is widely empolyed for pain relief, fever reduction, and the alleviation of inflammation in various conditions such as headaches, muscle pain, arthritis, and fever (7). Ibuprofen exerts its effects by inhibiting cyclooxygenase enzymes (COX-1 and COX-2), which are responsible for the production of prostaglandins compounds that contribute to inflammation and pain (8). Although effective, the long-term use of Ibuprofen or its use at high doses may lead to side effects such as gastrointestinal disturbances or kidney disorders. Therefore, its use should be administered with caution and under medical supervision (9).

Materials and methods:

In this study, twelve adult white laboratory rats, one month of age and weighing approximately 0.55 kg, were used. The animals were housed in wooden cages lined with wood shavings, and the cages were cleaned regularly to maintain hygiene (10). Six rats were placed in each cage. Appropriate environmental conditions were provided, including a temperature of 24 ±4°C and a 12-hour light/12-hour dark cycle. Food and water were provided ad libitum throughout the duration of the experiment. The rats were allowed a two-week acclimatization period before the start of the study (11).

Results

The results indicated that treatment with Ibuprofen led to noticeable effects, as the renal glomeruli appeared filled with a large number of white blood cells, alongside marked signs of severe congestion. The epithelial wall of the glomerulus appeared thickened in certain areas. These findings are indicative the presence of acute glomerulonephritis, likely corresponding to the exudative phase characterized by an accumulation of inflammatory cells, as shown in Figure (1).

Renal tubules appeared irregularly distributed, with some demonstrating noticeable dilation. The blood vesselse, particularly the capillaries were filled with red blood cells, indicating marked vascular congestion. This histopathological image is indicative of acute vascular congestion in the kidneys, possibly due to a sudden circulatory collapse or systemic shock, as illustrated in Figure (2).

Furthermore, the glomerulus shows a marked infiltration of inflammatory cells, along with evident changes in the epithelial cells within the glomerulus and the surrounding tubules. Additionally, the presence of necrotic (dead) cells indicates severe tissue injury. These findings support the diagnosis of acute glomerulonephritis with a possible necrotizing component, as demonstrated in Figure (3).

Longitudinal sections of the renal tubules revealed mild dilation and epithelial cells exhibiting degenerative changes. There were also blood-filled spaces within the capillaries. These alterations are suggestive of acute tubular degeneration, likely resulting from ischemia or nephrotoxic injury, as illustrated in Figure (4).

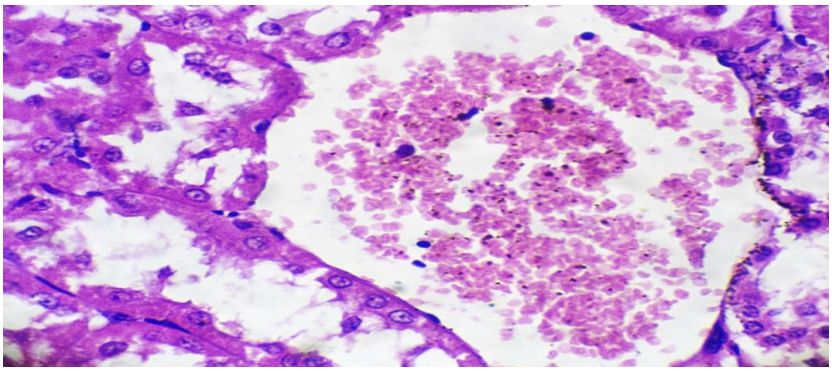

Figure(1)A transverse section of renal tissue shows a glomerulus markedly filled with a large number of white blood cells, along with prominent signs of severe vascular congestion.Stain: Hematoxylin and Eosin (H&E); Magnification: (10x).

ISSN Print:2790-6485 | ISSN Online : 2790-6477 Open Access

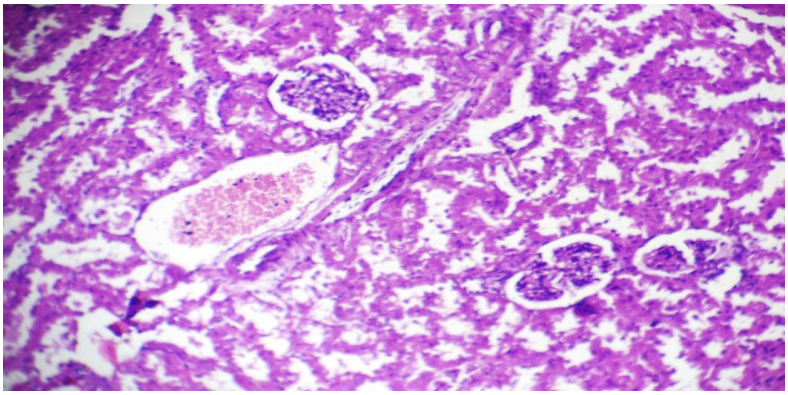

Figure(2)A transverse section of glomerular tissue reveals irregularly distributed renal tubules, with some appearing dilated. The blood vessels show signs of vascular congestion, particularly in the capillaries.(Stain: Hematoxylin and Eosin (H&E); Magnification: (10x).

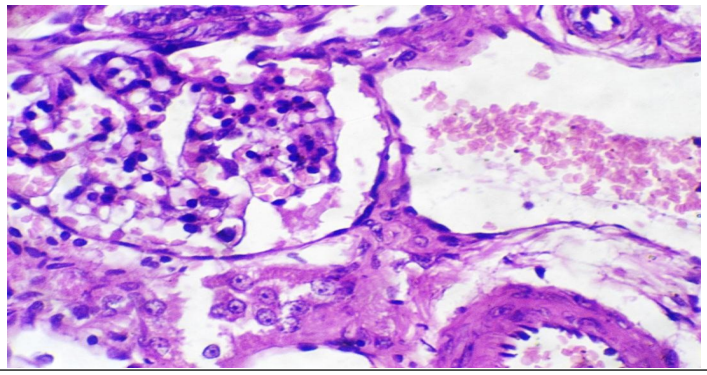

Figure(3)A transverse section of glomerular tissue shows the glomerulus with abundant inflammatory cell infiltration, along with epithelial cell alterations within both the glomerulus and the surrounding renal tubules.(Stain: Hematoxylin and Eosin (H&E); Magnification: (10x).

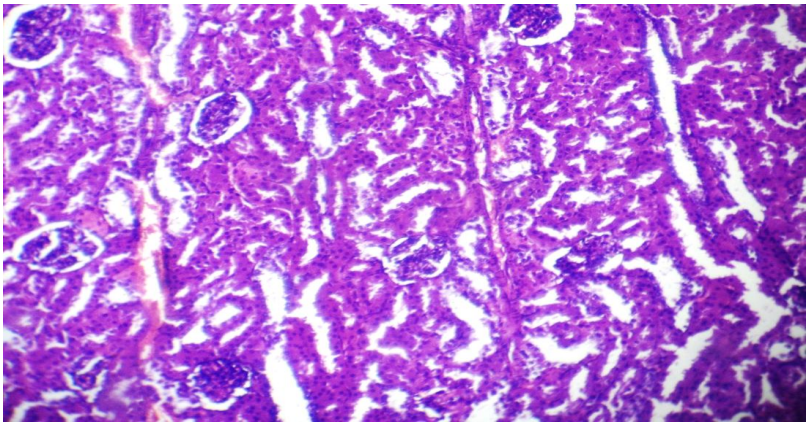

Figure(4)A longitudinal section of renal tubules reveals mild dilation and epithelial cells exhibiting degenerative changes.(Stain: Hematoxylin and Eosin (H&E); Magnification: (10x).

ISSN Print:2790-6485 | ISSN Online : 2790-6477 Open Access

Discussion:

The histopathological findings of this study revealed that the administration of Ibuprofen at a dose of 30 mg/kg resulted in distinct renal alterations, most notably within the glomeruli. The glomerular tufts appeared markedly congested and infiltrated with a large number of white blood cells. Additionally, localized thickening of the glomerular epithelial walls was observed, which correlates with the findings (12,13) (Figure 1). These changes are indicative of acute glomerulonephritis (AGN), likely representing the exudative or proliferative phase of the condition, characterized by the accumulation of inflammatory cells within the glomerular capillaries and mesangial matrix.

The thickened glomerular basement membrane and proliferation of epithelial cells are commonly associated with immune complex deposition, a mechanism frequently implicated in glomerular injury following exposure to nephrotoxic agents (14). These findings are in accordance with study (15) demonstrating that certain antibiotics or non-steroidal anti-inflammatory drugs can provoke immune-mediated glomerular inflammation, leading to mesangioproliferative or endocapillary proliferative patterns of injury.

In addition, the renal cortex exhibited significant alterations in tubular architecture and vascular perfusion. The renal tubules were observed to be irregularly distributed, with some showing marked luminal dilation, these results are agree with previous research (16,17) (Figure 2). This disorganization suggests early tubular injury, potentially resulting from ischemic or toxic insults. Tubular dilation may reflect obstructive phenomena or impaired reabsorption mechanisms, commonly seen in acute kidney injury (AKI) (18).

Furthermore, capillaries and other renal blood vessels appeared congested, with an abnormally high density of red blood cells, suggesting acute vascular congestion. Such congestion is a hallmark of hemodynamic compromise, frequently associated with drug-induced vasoconstriction (19). This form of vascular pathology can lead to regional hypoxia and secondary damage to the tubular epithelium (20).

Histopathological analysis of the current study revealed intense infiltration of inflammatory cells within the glomerular tufts, accompanied by notable alterations in the epithelial cells of both glomeruli and surrounding renal tubules. These results are align with those reported in other research (21,22,23) (Figure 3). The presence of necrotic cells further underscores the severity of the injury, suggesting progression from purely inflammatory damage to necrotizing glomerulonephritis (24).

This pattern is characteristic of acute glomerulonephritis (AGN), particularly subtypes involving immune complex deposition, where excessive immune activation results in endothelial and epithelial damage (25). Infiltration of neutrophils, lymphocytes, and mononuclear cells is a well-documented feature of the exudative phase, while epithelial cell swelling, degeneration, and necrosis may indicate progression toward crescentic or necrotizing glomerular injury (26). Necrotizing lesions in AGN often reflect a more aggressive immunopathological mechanism, potentially mediated by complement activation, or severe post-infectious glomerulonephritis (27).

Longitudinal histological sections of the renal tubules demonstrated mild luminal dilation and degenerative changes in the tubular epithelial cells. Another indicator of localized vascular congestion is the existence of blood-filled capillary gaps. These results correlate with the data reported (28,29) (Figure 4). Such features are indicative of acute tubular degeneration (ATD), a pathological condition frequently caused by renal ischemia or exposure to nephrotoxic agents (30). Tubular epithelial cell degeneration typically manifests as cellular swelling, cytoplasmic vacuolization, and loss of brush border integrity alterations (31,32), that compromise the reabsorptive and secretory functions of the nephron (33,34). Such cellular alterations often precede more severe forms of acute kidney injury, including acute tubular necrosis (ATN).

Ischemia-induced ATD is commonly associated with reduced renal perfusion pressure and oxygen deprivation, causing metabolic

ISSN Print:2790-6485 | ISSN Online : 2790-6477 Open Access

derangements and mitochondrial dysfunction in tubular cells (35). Similarly, nephrotoxicity from drugs may disrupt cellular homeostasis through oxidative stress and apoptosis pathways (36).

Conclusion:

1-Histopathological analysis showed that Ibuprofen induced acute glomerulonephritis, marked by leukocyte infiltration, epithelial wall thickening, and vascular congestion.

2-Necrosis and epithelial degeneration in the glomeruli and tubules suggest progression to a severe, likely necrotizing form of glomerulonephritis.

3-Severe erythrocyte congestion in renal capillaries indicates acute vascular compromise, possibly due to hypotension or impaired circulation.

4-Renal tubular disarray and epithelial degeneration are indicative of acute tubular damage, likely resulting from direct toxicity or ischemic injury.

5-The injury reflects a multifactorial renal pathology involving immune, vascular, and cytotoxic mechanisms affecting different segments of the nephron.

6-These findings emphasize the need to monitor renal histology during treatment with potentially nephrotoxic drugs and to investigate their underlying mechanisms further.

References:

1. Gulomovna, D. B., Dilafruz, O., & Durdonabegim, D. (2024). THE URINARY SYSTEM:A VITAL PLAYER IN HUMAN PHYSIOLOGY . Eurasian Journal of Medical and Natural Sciences, 4(1-1), 12-17.
2. Kumar, M., Dev, S., Khalid, M. U., Siddenthi, S. M., Noman, M., John, C., ... & AKUBUIRO, C. (2023). The bidirectional link between diabetes and kidney disease: mechanisms and management. Cureus, 15(9).
3. Li, X., Hu, J., Zhao, X., Li, J., & Chen, Y. (2022). Piezo channels in the urinary system. Experimental & Molecular Medicine, 54(6), 697-710.
4. Cook, M. A., & Wright, G. D. (2022). The past, present, and future of antibiotics. Science translational medicine, 14(657), eabo7793.
5. Zhang, Q. Y., Yan, Z. B., Meng, Y. M., Hong, X. Y., Shao, G., Ma, J. J., ... & Fu, C. Y. (2021). Antimicrobial peptides: mechanism of action, activity and clinical potential. Military Medical Research, 8(1), 48.
6. Terreni, M., Taccani, M., & Pregnolato, M. (2021). New antibiotics for multidrug-resistant bacterial strains: latest research developments and future perspectives. Molecules, 26(9), 2671.
7. Sohail, R., Mathew, M., Patel, K. K., Reddy, S. A., Haider, Z., Naria, M., ... & Patel, K. K. (2023). Effects of non-steroidal anti-inflammatory drugs (NSAIDs) and gastroprotective NSAIDs on the gastrointestinal tract: a narrative review. Cureus, 15(4).
8. Halim, P. A., El-Nassan, H. B., & El-Dash, Y. S. (2022). Design and synthesis of novel ibuprofen derivatives as selective COX-2 inhibitors and potential anti-inflammatory agents: evaluation of PGE2, TNF-α, IL-6 and histopathological study. Medicinal Chemistry, 18(4), 427-443.
9. Hnepa, Y. Y., Chopey, I. V., Chubirko, K. I., & Bratasyuk, A. M. (2021). Short-and long-term effects of NSAIDs on the gastrointestinal mucosa: complex analysis of benefits and complications prevention. Wiad Lek, 74(4), 1011-1018.
10. Can, M. E. (2020). Hygiene conditions and animal-environment relations in farm animals barns. Black Sea Journal of Engineering and Science, 3(2), 64-70.
11. Figueroa, X. A., Vogeli, G., & Butters, B. M. (2024). Magnetic Field Emulations of Small Inhibitor RNA: Effects on Implanted GL261 Tumors in C57BL/6 Immune Competent Mice. Open Journal of Biophysics, 14(4), 339-354.
12. Tang, Y., Liu, J., & Zhang, L. (2021). Pathological classification and molecular mechanisms of drug-induced glomerulonephritis. Frontiers in Medicine, 8, 657943.
13. Kumar, R., & Kalra, J. (2022). Immune-mediated glomerular diseases: updates in pathogenesis and treatment. Kidney International Reports, 7(1), 23–34. `
14. Wu, C. Y., Lin, Y. H., & Chen, C. C. (2023). Drug-related acute glomerular injury: clinical and histopathological spectrum. BMC Nephrology, 24, 88.

ISSN Print:2790-6485 | ISSN Online : 2790-6477 Open Access

15. Lee, H., Choi, J. Y., & Park, H. S. (2021). Nephrotoxicity and glomerular inflammation caused by antibiotic exposure: A mechanistic study. Toxicologic Pathology, 49(4), 765–772.
16. Eldokmak, R. M., & Metwally, E. A. (2023). Effect of Garlic Oil on Sulfasalazine Induced Injury of Renal Tubules. Egyptian Journal of Histology, 46(1), 395-406.
17. Z Jawad N , W H Yahya , A K Abdulhussain , B A Nasir. (2025). A study of The effect of Alcoholic Extract of Celery Seeds on The Concentration of Sex Hormones in Male White Rats Treated with Depakine., Al-Harf Journal., No. 24 ., Vol. 1, March 2025
18. Y A Kareem Ali , E j Kadhum. (2025). Molecular Detection of HPV High-Risk Genotypes 16 and 18 in Women with Breast Tumors in Najaf Governorate., Al-Harf Journal., No. 24 ., Vol. 1, March 2025
19. Ghonimi, W. A., Alferah, M. A., Dahran, N., & El-Shetry, E. S. (2022). Hepatic and renal toxicity following the injection of copper oxide nanoparticles (CuO NPs) in mature male Westar rats: histochemical and caspase 3 immunohistochemical reactivities . Environmental Science and Pollution Research, 29(54), 81923-81937.
20. Zhou, H., Yao, J., & Wu, H. (2021). Tubular cell response to acute kidney injury: mechanisms and therapeutic strategies. Cell Death & Disease, 12, 573.
21. Zhang, M., He, Y., Wang, H., & Wang, S. (2022). Vascular congestion and tubular injury: intertwined mechanisms in acute kidney dysfunction. American Journal of Physiology-Renal Physiology, 322(4), F414–F424.
22. D G Kader ., M H Sagban. (2025). Evaluation of the Association Between Random Blood Glucose and Renal Function Markers in Obese Individuals., Al-Harf Journal ., No. 24 ., Vol. 3, August 2025
23. Guzzi, L. M., Giavarina, D., Marangoni, F., & Lombardi, C. (2023). Hemodynamic mechanisms of acute kidney injury: vascular congestion as a neglected factor. Current Opinion in Nephrology and Hypertension, 32(1), 48–56.
24. Bronstein, R., Pace, J., Gowthaman, Y., Salant, D. J., & Mallipattu, S. K. (2023). Podocyte-parietal epithelial cell interdependence in glomerular development and disease. Journal of the American Society of Nephrology, 34(5), 737-750.
25. Walker, P. D., Becker, J. U., & Fogo, A. B. (2022). Technical Aspects of Renal Pathology. Pediatric Nephrology, 213-234.
26. Moll, S., Angeletti, A., Scapozza, L., Cavalli, A., Ghiggeri, G. M., & Prunotto, M. (2021). Glomerular macrophages in human auto- and allo-immune nephritis. Cells, 10(3), 603.
27. Mosquera-Sulbaran, J. A., Pedreañez, A., Vargas, R., & Hernandez-Fonseca, J. P. (2024). Apoptosis in post-streptococcal glomerulonephritis and mechanisms for failed of inflammation resolution. Pediatric Nephrology, 39(6), 1709-1724.
28. Kitching, A. R., & Holdsworth, S. R. (2022). Glomerulonephritis: pathogenesis and progression. Nature Reviews Nephrology, 18(3), 175–186.
29. Leclerc, M., Bourdenet, G., & Dahan, K. (2023). Crescentic and necrotizing glomerulonephritis: diagnostic challenges and update on treatment. Current Opinion in Nephrology and Hypertension, 32(1), 11–18.
30. Salama, A. D., Little, M. A., & Jayne, D. R. (2021). ANCA-associated vasculitis and glomerulonephritis: update on pathogenesis and treatment. Current Opinion in Rheumatology, 33(1), 39–45.
31. Badawy, S., Abd-Elraouf, M., Gab-Allah, M. S., El-Mashad, A. B. I., Tantawy, A. A., & Amin, A. A. (2024). Renoprotective potential of olive leaves extract against cadmium-induced chronic kidney damage. Journal of Advanced Veterinary Research, 14(1), 65-70.
32. Mohammed, M. Z., Abdelrahman, S. A., El-Shal, A. S., Abdelrahman, A. A., Hamdy, M., & Sarhan, W. M. (2024). Efficacy of stem cells versus microvesicles in ameliorating chronic renal injury in rats (histological and biochemical study). Scientific Reports, 14(1), 16589.
33. Foster, K., Hammad, A., & Browne, R. (2022). Histopathology of acute tubular injury: clinical implications. Journal of Nephropathology, 11(1), e21-45.
34. Wang, W., & Humphreys, B. D. (2023). Tubular injury and regeneration in acute kidney injury. Annual Review of Pathology: Mechanisms of Disease, 18, 133–154.

ISSN Print:2790-6485 | ISSN Online : 2790-6477 Open Access

35. Liang, X., Gao, F., & Chen, X. (2021). Mitochondrial dysfunction in ischemic acute kidney injury: pathophysiology and therapeutic approaches. Frontiers in Physiology, 12, 656142.
36. Jin, S., Chen, X., & Zhang, Y. (2023). Mechanisms of drug-induced nephrotoxicity and protective strategies. Pharmacology & Therapeutics, 246, 108375.