Kuwait Research Journal of
Agriculture And Life Science

ISSN Print: 2790-6485 | ISSN Online :2790-6477 Open Access

A Study on the Histological Effects of the Antibiotic Gentamicin on the Renal Structure of White Rats

Noor M. Hasnawi[1], Dhurgham Q. Shaheed[2]
[1]Al-Furat Al-Awsat Technical University , Najaf Technical Institute ,Department of Forensic and Judicial Evidence Techniques
[2]College of Pharmacy University of Al Kafeel, Najaf, Iraq

*Corresponding Author

Noor M. Hasnawi
white rats, electron, histology, pathology

Article History
Received: 20.06.2025
Revise : 22.07.2025
Accepted: 26.07.2025
Published: 04.08.2025

DOI:10.61705/KRJALS.4.2.2025.1.5

Keywords: Kazem sebty, poetry, intertextuality.

Abstract: The study involved the use of 12 laboratory white rats, which were divided into two groups, each containing 12 rats. The animals were injected with Gentamicin at a concentration of 40 mg/mL for a period of three weeks. At the end of the dosing period, all animals were sacrificed and dissected to investigate the drug's effect on the renal histological structure. Histological examination using a scanning electron microscope revealed pathological histological changes in the kidneys compared to the control group.

Introduction

Gentamicin is a broad-spectrum aminoglycoside antibiotic commonly used to treat serious bacterial infections, particularly those caused by Gram-negative bacteria. It works by inhibiting bacterial protein synthesis, ultimately leading to cell death. Gentamicin is administered via injection and is widely used in both clinical and experimental settings, though it carries a risk of nephrotoxicity and ototoxicity(1).

The kidney is a vital organ responsible for filtering waste products, excess fluids, and toxins from the blood to form urine. It plays a central role in maintaining electrolyte balance, blood pressure regulation, and overall homeostasis. Each rat has two kidneys, and their health is critical for proper metabolic and physiological function (2) .

Methods – Experimental Animals

In this study, 12 adult white laboratory rats, aged one month, were used. The rats were housed in wooden cages with floors lined with wood shavings, and cleanliness was maintained regularly to ensure a healthy environment. The animals were distributed at a rate of 6 rats per cage. Appropriate environmental conditions were provided, including a controlled temperature of (24 ± 4)°C and a light/dark cycle of 12 hours light and 12 hours darkness. Food and water were supplied freely (ad libitum) throughout the experimental period. A two-week acclimatization period was allowed before the commencement of the study (3).

Results:

Histological changes:

The scanning electron microscopy (SEM) image of the untreated kidney tissue reveals a well-

ISSN Print: 2790-6485 | ISSN Online :2790-6477 Open Access

preserved and organized tubular architecture. The tubular cells appear intact with smooth and continuous cell membranes, indicating the absence of cellular degeneration or necrosis. No abnormal surface perforations or interstitial spaces are observed, and the overall tissue morphology is regular and compact. These features confirm the structural integrity and normal histological appearance of healthy renal tissue, serving as a baseline for comparison with gentamicin-treated samples as for Image 1

The current study, based on scanning electron microscopy (SEM) findings, revealed the following observations: a large, heterogeneous area with a rough texture and a lack of normal cellular organization. Evidence of atrophy in the tubular structure and undulating cellular surfaces was noted, indicating membrane degradation. Additionally, the borders between tubular cells appeared indistinct, as shown in Image 2.

In Image 3, fine structural deformities were observed in the cell membrane, along with the presence of surface perforations and irregular depressions, suggesting focal necrosis or cellular erosion.
Image 4 demonstrated wide interstitial spaces not typically present in healthy kidney tissue. There were also signs of tissue tearing and disorganization, with blurred boundaries of the renal tubules.
As for Image 5, it showed an open tissue architecture characterized by prominent pores and voids, indicating extensive disintegration of cellular structures. The overall tissue appearance was irregular and lacked the normal tubular architecture.

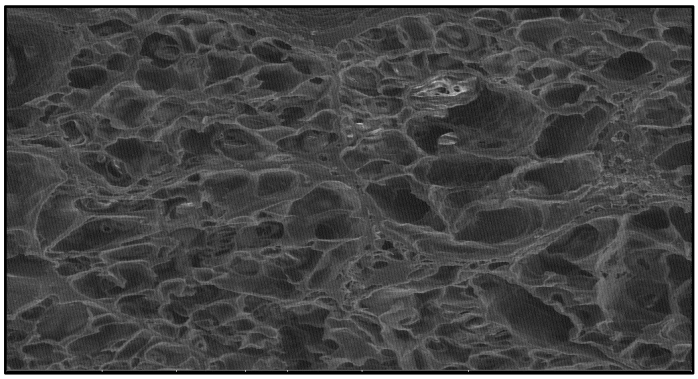

Figure (1): A transverse section of testicular tissue from the Gentamicin-treated group after a three-week period, showing The tubular cells appeared intact with smooth, connected cell membranes, indicating the absence of any cellular degeneration or necrosis. No surface perforations or abnormal interstitial spaces were observed and served as a basis for comparison with the gentamicin-treated samples.

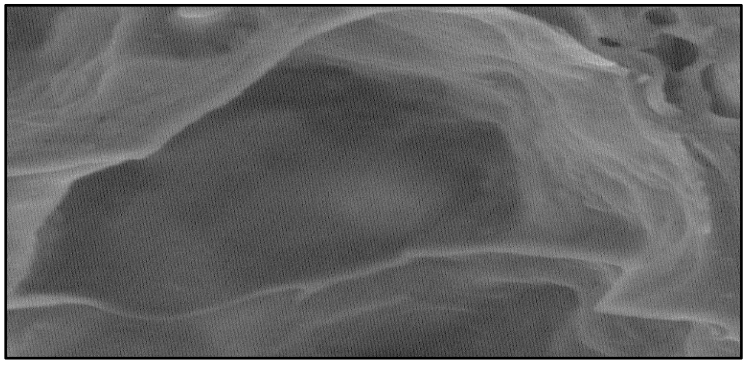

ISSN Print: 2790-6485 | ISSN Online :2790-6477 Open Access

Figure (2): A transverse section of testicular tissue from the Gentamicin-treated group after a three-week period, showing cellular organization. Evidence of tubular atrophy and wavy cell surfaces were observed, indicating membrane degradation. In addition, the boundaries between tubular cells appeared blurred.

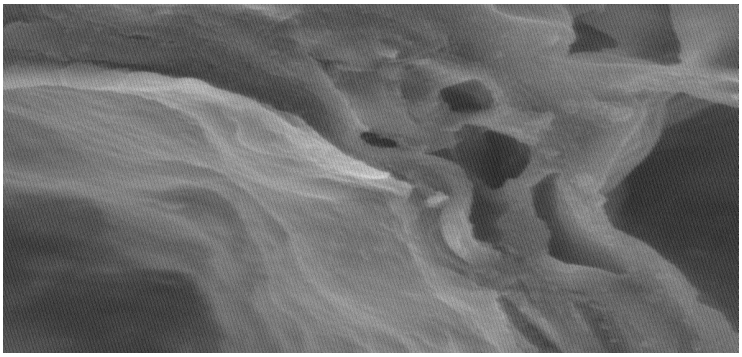

Figure (3): A transverse section of testicular tissue from the Gentamicin-treated group after a three-week period, showing a large, heterogeneous area with a rough texture and a lack of normal cellular organization. Evidence of atrophy in the tubular structure and undulating cellular surfaces was noted, indicating membrane degradation. Additionally, the borders between tubular cells appeared indistinct

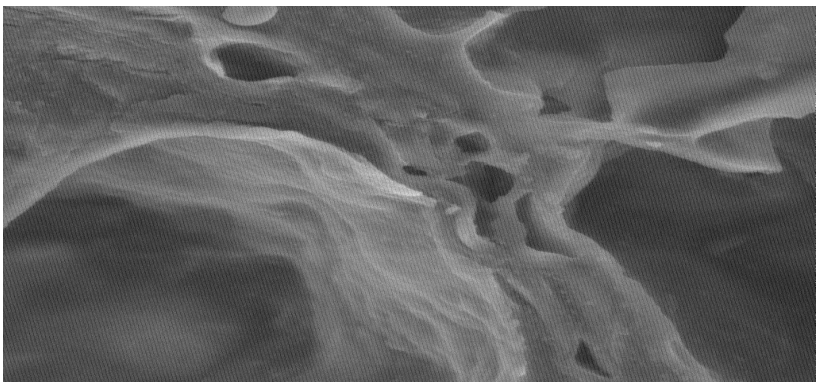

Figure (4): A transverse section of testicular tissue from the Gentamicin-treated group after a three-week period, showing demonstrated wide interstitial spaces not typically present in healthy kidney tissue. There were also signs of tissue tearing and disorganization, with blurred boundaries of the renal tubules.

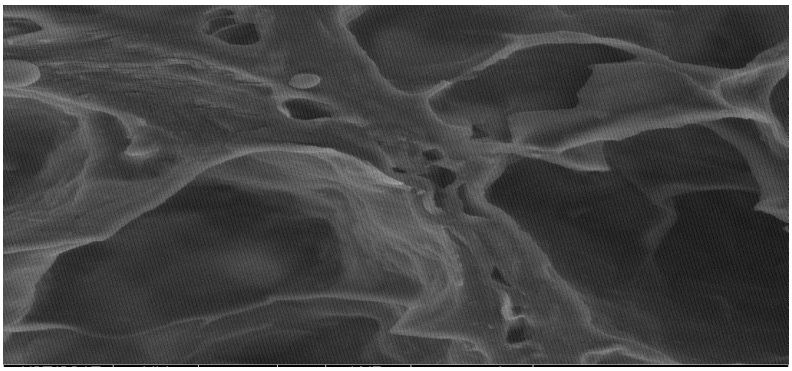

ISSN Print: 2790-6485 | ISSN Online :2790-6477 Open Access

Figure (5): A transverse section of testicular tissue from the Gentamicin-treated group after a three-week period, showing tissue architecture characterized by prominent pores and voids, indicating extensive disintegration of cellular structures. The overall tissue appearance was irregular and lacked the normal tubular architecture

Discussion:

The present study investigated the nephrotoxic effects of Gentamicin on renal tissue using scanning electron microscopy (SEM) to identify ultrastructural changes. The findings revealed a stark contrast between the kidney tissue of untreated control animals and that of the Gentamicin-treated group.

In the control group (Image 1), renal tissue displayed a well-organized tubular architecture, with smooth and intact cellular membranes and clearly defined tubular borders. These features indicate a healthy and functional nephron structure, serving as a baseline for comparison (4).

In contrast, the Gentamicin-treated group exhibited progressive histopathological alterations indicative of nephrotoxicity. Image 2 revealed large, heterogeneous areas with a rough texture and disorganized cellular arrangement, alongside signs of tubular atrophy and membrane undulation, suggesting early degenerative changes. This aligns with the known mechanism of Gentamicin-induced nephrotoxicity, which involves accumulation in proximal tubular cells and the generation of reactive oxygen species, leading to oxidative damage and mitochondrial dysfunction (5).

As shown in Image 3, further deterioration was observed in the form of fine membrane deformities, surface perforations, and irregular depressions, which point to focal necrosis and erosion. These morphological disruptions compromise the integrity of tubular reabsorption and secretion, potentially affecting renal function (6).

Image 4 presented significantly widened interstitial spaces and loss of tubular boundaries, suggesting interstitial edema and advanced tissue damage. This could be attributed to cell membrane rupture and inflammatory infiltration, common consequences of sustained Gentamicin exposure (7).

Finally, Image 5 revealed extensive disintegration of renal tissue, with open architecture, large voids, and the complete loss of normal tubular morphology. These findings indicate irreversible structural collapse and confirm the cumulative nature of Gentamicin-induced toxicity when administered over extended periods (8).

These results are consistent with previous studies demonstrating that Gentamicin primarily affects the proximal tubules, initiating a cascade of degenerative changes that may progress to acute tubular necrosis if unmitigated. The observed changes underline the functional consequences of structural damage, particularly the risk of reduced glomerular filtration and electrolyte imbalance (9).

While the study provides compelling evidence of Gentamicin's nephrotoxicity, limitations include the relatively small sample size and the use of a single dosage and exposure duration. Future research should explore time-dependent changes, dose-response relationships, and potential protective agents, such as antioxidants, to mitigate renal damage (10).

In conclusion, the SEM analysis confirmed that Gentamicin administration at 40 mg/kg for three weeks induces severe structural damage to renal tissue in rats, progressing from mild degeneration to widespread necrosis and architectural collapse. These findings reinforce the need for cautious clinical use of aminoglycosides and highlight the importance of monitoring renal function during therapy (11).

Conclusions

The scanning electron microscopy analysis confirmed that Gentamicin administration at 40 mg/kg for three weeks induces severe structural damage to renal tissue in rats, progressing from mild degeneration to widespread necrosis and architectural collapse

References:

1. Karunarathna, I., Gunasena, P., Gunathilake,

ISSN Print: 2790-6485 | ISSN Online :2790-6477 Open Access

S., & De Alvis, K. (2024). Understanding gentamicin-induced nephrotoxicity and ototoxicity: Prevention and management.
2. Hasnawi, N. M. (2024). Effect of nano-extract of Nigella sativa seeds on the histological structure Effect of nano-extract of Nigella sativa seeds on the histological structure of the kidneys in male albino rats treated with Tartrazine of the kidneys in male albino rats treated with Tartrazine. Maaen Journal for Medical Sciences, 3(4).
3. dos Santos Alves, E. M., de Araújo, F. W. C., Soares, P. C., da Silva, L. A. R., de Araújo Gonçalves, D. N., & do Nascimento, E. (2024). Reestablishment of ad libitum feeding following partial food deprivation: Impact on locomotor activity, visceral fat, food intake, and circadian glycemic curve. Chronobiology International, 41(7), 941-958.
4. Z Jawad N , W Hashim Y ,A K Abdulhussain , B A Nasir. (2025). A study of The effect of Alcoholic Extract of Celery Seeds on The Concentration of Sex Hormones in Male White Rats Treated with Depakine., Al-Harf Journal., No. 24 .,Vol. 1, March 2025
5. Schwartz, G. J., & Rashid, M. (2021). Overview, structure, and function of the nephron. Pediatric Critical Care: Text and Study Guide, 863-909.
6. Gamaan, M. A., Zaky, H. S., & Ahmed, H. I. (2023). Gentamicin-induced nephrotoxicity: A mechanistic approach. Azhar International Journal of Pharmaceutical and Medical Sciences, 3(2), 11-19.
7. Allen, H., Barnthouse, N. C., & Chan, B. Y. (2022). Periosteal pathologic conditions: imaging findings and pathophysiology. Radiographics, 43(2), e220120.
8. Yu Y, Zhang Q, Deng Z. (2017). "Parallel pathways in the biosynthesis of aminoglycoside antibiotics". F1000Research. 6: 723 . doi:10.12688/f1000research.11104.1.
9. Kore K.J., Shete R.V., Kale B.N., Borade A.S. Protective role of hydroalcoholic extract of Ficus carica in gentamicin induced nephrotoxicity in rats. Int. J. Pharm. Life Sci. 2011;(2):978–982.
10. Abd-Elhakim, Y. M., Abdel-Motal, S. M., Malhat, S. M., Mostafa, H. I., Ibrahim, W. M., Beheiry, R. R., ... & Said, E. N. (2022). Curcumin attenuates gentamicin and sodium salicylate ototoxic effects by modulating the nuclear factor-kappaB and apoptotic pathways in rats. Environmental Science and Pollution Research, 29(60), 89954-89968.
11. Alyaa Neamah Najm Alsaedi , Faten Hadi Fakhri. (2025). Study Review: Chemical functionalization of Nanomaterials for Enhanced Biocompatibility and Cellular Uptake., Al-Harf Journal., No. 24 ., Vol. 1, March 2025
12. McGregor, T., & Jones, S. (2021). Fluid and electrolyte problems in renal dysfunction. Anaesthesia & Intensive Care Medicine, 22(7), 406-409.
13. Dhanarajan R., Abraham P., Isaac B. Protective effect of Ebselen, a selenoorganic drug, against gentamicin-induced renal damage in rats. Basic Clin. Pharmacol. Toxicol. 2006;99(3):267–272. doi: 10.1111/j.1742-7843.2006.pto_474.x
14. Sharma R., Rajani G.P., Sharma V., Komala N. Effect of ethanolic and aqueous extracts of Bauhinia variegata Linn. on gentamicin-induced nephrotoxicity in rats. Ind. J. Pharm. Educ. Res. 2011;45(2):192–198
15. Sacks, B., Onal, H., Martorana, R., Sehgal, A., Harvey, A., Wastella, C., ... & Chen, Q. (2021). Mitochondrial targeted antioxidants, mitoquinone and SKQ1, not vitamin C, mitigate doxorubicin-induced damage in H9c2 myoblast: pretreatment vs. co-treatment. BMC Pharmacology and Toxicology, 22, 1-16.
16. Sacks, B., Onal, H., Martorana, R., Sehgal, A., Harvey, A., Wastella, C., ... & Chen, Q. (2021). Mitochondrial targeted antioxidants, mitoquinone and SKQ1, not vitamin C, mitigate doxorubicin-induced damage in H9c2 myoblast: pretreatment vs. co-treatment. BMC Pharmacology and Toxicology, 22, 1-16.